Brian P. Kavanagh, M.B., F.R.C.P.C., Editor

Application of Focused Assessment Ultrasound in Trauma to Perioperative Medicine

A Tool to Quickly Diagnose Postoperative Hemorrhage

Stephen M. Howell, M.D., David A. Bennion, M.D., Nezar Jrebi, M.D., Hong Wang, M.D., Ph.D.

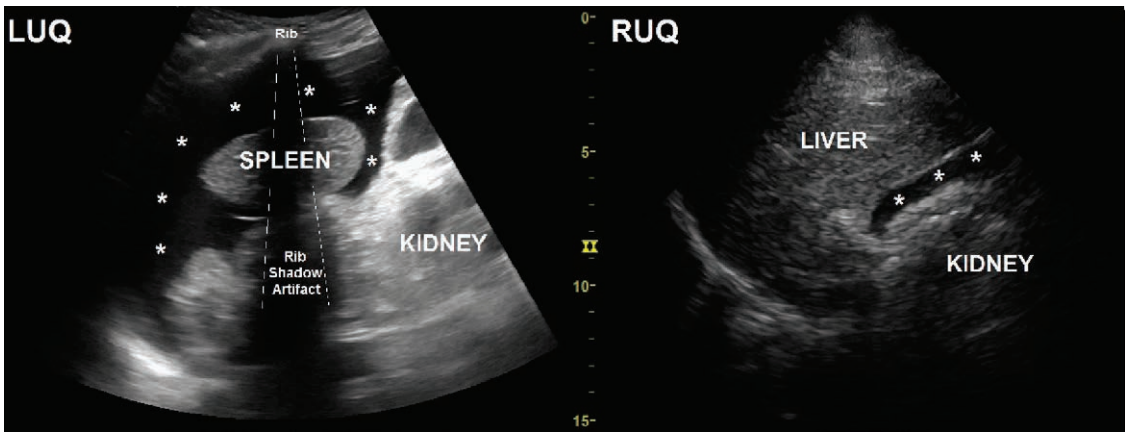

THE focused assessment ultrasound in trauma exam is a well established screening and diagnostic tool in the setting of trauma but is not widely utilized perioperatively. The sonograms shown in the figure depict free fluid (asterisks) surrounding the spleen (LUQ = left upper quadrant) and at the hepatorenal interface (RUQ = right upper quadrant), which led to immediate surgical reexploration after a routine hemicolectomy. Approximately 2 l of hematoma was evacuated, which was due to unrecognized liver laceration.

One of the objectives of the focused assessment ultrasound in trauma exam is to assess free fluid in the pericardial, peritoneal, and pleural cavities.[1] Focused assessment ultrasound in trauma examination windows include subxiphoid for pericardial fluid, right upper and left upper quadrant for pleural and intraabdominal free fluid and suprapubic for free pelvic fluid. Free fluid tends to collect in dependent areas. Trendelenburg, reverse Trendelenburg, right lateral, and left lateral decubitus positions can increase the sensitivity for detecting free fluid in the upper abdomen, pelvis, hepatorenal interface, and splenorenal interface, respectively. Currently, there is no standard free fluid scoring system. The hemoperitoneum score, comprised of the diameter of the largest fluid collection in centimeters plus one point for each positive focused assessment ultrasound in trauma view, may help predict the need for surgical exploration when the value is greater than 3.[2] The decision of when and if to operate should also be based on the clinical scenario.

Although ultrasound equipment is readily available in most operating rooms, point-of-care ultrasound continues to be underutilized.[3] Ultrasonography is a valuable adjunct to the physical exam and can greatly assist with perioperative decision-making.

Competing Interests

The authors declare no competing interests.

Correspondence

Address correspondence to Dr. Wang: hong.wang1@wvumedicine.org

References

1. American College of Emergency Physicians. Emergency ultrasound imaging criteria compendium. Ann Emerg Med 2006; 48:487–510
2. McKenney KL, McKenney MG, Cohn SM, Compton R, Nunez DB, Dolich M, Namias N: Hemoperitoneum score helps determine need for therapeutic laparotomy. J Trauma 2001; 50:650–6
3. Janelle GM, London MJ: Perioperative ultrasound: The future is now. Anesth Analg 2016; 122:1734–6

Charles D. Collard, M.D., served as Handling Editor for this article.

From the Departments of Anesthesiology (S.M.H., D.A.B., H.W.) and Surgery (N.J.), West Virginia University, Morgantown, West Virginia.

Copyright © 2018, the American Society of Anesthesiologists, Inc. Wolters Kluwer Health, Inc. All Rights Reserved. Anesthesiology 2018; 129:333

Downloaded from http://pubs.asahq.org/anesthesiology/article-pdf/129/2/333/381148/20180800_0-00026.pdf by guest on 23 April 2024

Copyright © 2018, the American Society of Anesthesiologists, Inc. Wolters Kluwer Health, Inc. Unauthorized reproduction of this article is prohibited.
<zdoi;10.1097/ALN.0000000000002170>