

Extremely Prolonged Vecuronium Clearance in a Brain Death Case

Motoshi Kainuma, M.D., Ph.D.,* Toshiyuki Miyake, M.D., Ph.D.,† Tetsuo Kanno M.D., Ph.D.‡

VECURONIUM is commonly used in the critical care setting. One reason is its relatively short duration of action, which allows clinical assessment of patients within a few hours after discontinuing administration of the drug. We recently encountered a case in which extremely prolonged vecuronium action was observed.

Case Report

An otherwise healthy 61-yr-old woman weighing 42 kg lost consciousness in her bathroom in June 2000. At the time of arrival in the emergency room, she had a Glasgow Coma Scale score of 4, a blood pressure of 178/72 mmHg, a heart rate of 78 beats/min, and a respiratory rate of 22 breaths/min. She underwent tracheal intubation, and computerized tomography of the head was performed. The scan showed subarachnoid and intraventricular hemorrhage. Because of her poor neurologic condition, conservative therapy with controlled ventilation was chosen. Propofol and vecuronium were intravenously administered at 70 and 4 mg/h, respectively, for 15 h 40 min to ensure immobility and to control blood pressure. Neuromuscular function was not monitored. Rectal temperature was maintained between 34 and 35°C. Phenytoin, 250 mg/day, was administered, and in addition, she received hydrocortisone, cefotiam, aztreonam, and mannitol. The family reported no history of renal disturbance. Blood urea nitrogen and serum creatinine concentrations were 15 and 0.7 mg/dl, respectively, at the time of admission.

On the second hospital day, her pupils were fully dilated, and her electroencephalogram was isoelectric. Her family voluntarily presented an organ donor card in the patient's own writing. To allow a diagnosis of brain death, the propofol and vecuronium infusions were stopped. At the time of their discontinuation, blood urea nitrogen and serum creatinine concentrations were 27 and 1.6 mg/dl, respectively. Serum concentrations of alanine aminotransferase, aspartate aminotransferase, and bilirubin were within normal limits.

Twenty-three hours after discontinuation of propofol and vecuronium, we attempted to confirm the return of normal neuromuscular function, using ulnar nerve stimulation. Marked fade to tetanic stimulation was noted. Therefore, we assessed neuromuscular transmission by accelerometer (TOF-Guard; Biometer, Odense, Denmark). A train-of-four stimulus was applied over the ulnar nerve, and the evoked responses were measured at the adductor pollicis muscle. The T4/T1 ratio was only 25%. Subsequent administration of neostigmine increased this to 50%. Results of a subsequent nerve conduction study and electromyography were normal. At this time, blood concentrations of vecuronium and its active metabolite 3-desacetylvecuronium mea-

sured by liquid chromatography-tandem mass spectrometry were 33.3 and 81.0 ng/ml, respectively (table 1).

Fifty-seven hours after discontinuation of vecuronium, the train-of-four ratio reached a value greater than 75%. Sixty-four hours after discontinuation, urinary output progressively increased to 10,270 ml/day. Aggressive fluid replacement and 3-5 $\mu\text{g} \cdot \text{kg}^{-1} \cdot \text{min}^{-1}$ intravenous dopamine were used. Systolic blood pressure, central venous pressure, and heart rate were maintained at approximately 90-100 mmHg, 8-10 mmHg, and 80-85 beats/min, respectively. Serum sodium, potassium, calcium, and magnesium concentrations were maintained within normal limits.

Sixty four hours after discontinuation of vecuronium, the patient's train-of-four ratio was consistently greater than 80%. Blood concentrations of vecuronium and 3-desacetylvecuronium were 15.6 and 65.2 ng/ml, respectively (table 1). Although she was now deemed as meeting the legal requirements for a diagnosis of brain death, ultrasound examination showed polycystic lesions on the kidneys, which were considered to be unsuitable for transplantation.

Discussion

The prolonged neuromuscular blockade observed in this case is potentially explained by slow clearance of vecuronium and its metabolite, 3-desacetylvecuronium.¹ The normal elimination half-life of vecuronium in healthy volunteers is 25-61 min, whereas that of 3-desacetylvecuronium is approximately threefold longer.² 3-Desacetylvecuronium is 70% as potent as vecuronium.³ A median concentration of 123 ng/ml 3-desacetylvecuronium produces 50% depression of twitch tensions.² This is generally consistent with our own observed train-of-four ratios and blood concentrations of vecuronium and 3-desacetylvecuronium (table 1).

Although animal data suggest that the liver is the main organ of elimination of 3-desacetylvecuronium as well as vecuronium,⁴ many reports show that renal failure is associated with high plasma concentrations of 3-desacetylvecuronium and prolonged paralysis.^{1,2,5} In general, uremia decreases the hepatic clearance of many drugs that are eliminated principally by the liver. Caldwell *et al.*² predicted that the ratio of the steady-state concentrations of 3-desacetylvecuronium and vecuronium would be approximately 0.2, using the values obtained in their study. However, plasma concentrations of 3-desacetylvecuronium exceeded those of vecuronium in our patient (table 1). There could be either disproportionately decreased clearance of 3-desacetylvecuronium relative to vecuronium or increased metabolic conversion of vecuronium to 3-desacetylvecuronium, associated with renal disturbance in this patient.²

Prolonged neuromuscular blockade in this patient may be related to her preexisting polycystic kidney. This disease is characteristic by the progressive enlargement

* Associate Professor of Anesthesiology, † Professor and Chairman of Anesthesiology, Department of Anesthesiology, ‡ Professor and Chairman of Neurosurgery, Department of Neurosurgery.

Received from the Departments of Anesthesiology and Critical Care Medicine, Fujita Health University, Aichi, Japan. Submitted for publication August 14, 2000. Accepted for publication April 2, 2001. Support was provided solely from institutional and/or departmental sources.

Address reprint requests to Dr. Kainuma: Department of Anesthesiology, Fujita Health University, 1-98 Dengakugakubo, Kutsukake-cho, Toyoake, Aichi, 470-1192, Japan. Address electronic mail to: mkainuma@fujita-hu.ac.jp. Individual article reprints may be purchased through the Journal Web site, www.anesthesiology.org.

Table 1. Blood Concentrations of Vecuronium and 3-Desacetylvecuronium after Cessation of Intravenous Vecuronium Administration

Time after Discontinuation (h)	TOF Ratio (%)	Vecuronium (ng/ml)	3-Desacetylvecuronium (ng/ml)
23 (serum)	25	33.3	81.0
43 (serum)	28	31.1	91.1
45 (serum)	45	27.2	84.2
45 (urine)	45	47.1	127.3
64 (serum)	82	15.6	65.2

TOF = train-of-four.

of a portion of renal tubule segments, typically causing renal insufficiency by the fifth or sixth decade of life.⁶ It is often accompanied by cerebral aneurysms.⁶ Potential renal parenchymal ischemia may be caused by cyst expansion, which might worsen along with progression of diabetes insipidus in this case.

Other possible coexistent factors might influence clearance of vecuronium and 3-desacetylvecuronium in this patient. Metabolic acidosis and electrolyte abnormalities, including hypermagnesemia, are reportedly variables associated with prolonged neuromuscular blockade.¹ However, these values were meticulously corrected. Phenytoin might alter the neuromuscular response to vecuronium.⁷ Administration of corticosteroids to patients with long-term use of nondepolarizing neuromuscular agents has been implicated as a cause of prolonged muscle weakness.^{8,9} Mannitol might also influence the clearance of vecuronium.¹⁰ However, insufficient data are available regarding these issues to permit further speculation.

In Japan, the diagnosis of brain death requires confirmation of no residual effect of muscle relaxants because these are believed to potentially influence the decision-

making process, *e.g.*, interfering with examination of the swallowing reflex.¹¹ The measurement of blood concentrations of vecuronium and 3-desacetylvecuronium were not mandated as part of legal decision making in this case, but their measurement fortuitously revealed the extremely prolonged clearance of vecuronium and its primary metabolite.

The authors thank Naosuke Sugai, M.D., Ph.D. (Department of Anesthesiology, Chigasaki Tokushukai Medical Center, Kanagawken, Japan), for valuable comments in preparing the manuscript.

References

- Segredo V, Caldwell JE, Matthey MA, Sharma ML, Gruenke LD, Miller RD: Persistent paralysis in critically ill patients after long-term administration of vecuronium. *N Engl J Med* 1992; 327:524-8
- Caldwell JE, Szenohradszy J, Segredo V, Wright PMC, McLoughlin C, Sharma ML, Gruenke LD, Fisher DM, Miller RD: The pharmacodynamics and pharmacokinetics of the metabolite 3-desacetylvecuronium (ORG 7268) and its parent compound, vecuronium, in human volunteers. *J Pharmacol Exp Therap* 1994; 270:1216-22
- Marshall IG, Gibb AJ, Durant NN: Neuromuscular and vagal blocking actions of pancuronium bromide, its metabolites, and vecuronium bromide (Org NC45) and its potential metabolites in the anesthetized cat. *Br J Anesth* 1983; 55:703-14
- Segredo V, Shin YS, Sharma ML, Gruenke LD, Caldwell JE, Khuenl-Brady KS, Agoston S, Miller RD: Pharmacokinetics, neuromuscular effects, and biodisposition of 3-desacetylvecuronium (Org 7268) in cats. *ANESTHESIOLOGY* 1991; 74:1052-9
- Lynam DP, Cronnelly R, Castagnoli KP, Canfell PC, Caldwell J, Arden J, Miller RD: The pharmacodynamics and pharmacokinetics of vecuronium in patients anesthetized with isoflurane with normal renal function or with renal failure. *ANESTHESIOLOGY* 1988; 69:227-31
- Grantham JJ: Polycystic kidney disease: A predominance of giant nephrons. *Am J Physiol* 1983; 244:F3-10
- Platt Pr, Thackray NM: Phenytoin-induced resistance to vecuronium. *Anaesth Intensive Care* 1993; 21:185-91
- Barohn RJ, Jackson CE, Rogers SJ, Ridings LW, McVey AL: Prolonged paralysis due to nondepolarizing neuromuscular blocking agents and corticosteroids. *Muscle Nerve* 1994; 17:647-54
- Kindler CH, Verotta D, Grey AT, Gropper MA, Yost CS: Additive inhibition of nicotinic acetylcholine receptors by corticosteroids and the neuromuscular blocking drug vecuronium. *ANESTHESIOLOGY* 2000; 92:821-32
- Matteo RS, Nishitaten K, Pua EK, Spector S: Pharmacokinetics of d-tubocurarine in man: effect of an osmotic diuretic on urinary excretion. *ANESTHESIOLOGY* 1980; 52:335-8
- Isono S, Ide K, Kochi T, Mizuguchi T, Nishino T: Effects of partial paralysis on the swallowing reflex in conscious humans. *ANESTHESIOLOGY* 1991; 75:980-4

Successful Resuscitation of a Child after Exsanguination Due to Aorto-esophageal Fistula from Undiagnosed Foreign Body

Eckehard A. E. Stuth, M.D.,* Astrid G. Stucke, M.D.,† Roger D. Cohen, M.D.,‡ Robert D. B. Jaquiss, M.D.,§ Subra Kugathasan, M.D.,|| S. Bert Litwin, M.D.#

FOREIGN bodies in the esophagus can cause pressure necrosis of the esophageal wall that may lead to perforation, mediastinitis, and formation of an aorto-esophageal fistula (AEF).¹ Patients may present with the typical "Chiari triad" of midthoracic pain, a sentinel hemorrhage of bright red blood, and exsanguination hours to days later.²

We report the successful resuscitation of a child who had exsanguination from an undiagnosed AEF caused by unsuspected foreign body ingestion. We believe that our patient's survival was due to immediate, aggressive volume resuscitation and temporary control of the fistula by inflation of an intraoperatively placed esophageal balloon catheter.

Case Report

A 7-yr-old, 35-kg girl with a history of epilepsy treated with valproic acid presented to an outlying hospital after she had vomited small amounts of dark brown blood. Her only complaints were moderate midepigastric pain on deep palpation. The patient's hematocrit was 31. After a second emesis of moderate amounts of dark brown blood, she was transferred to Children's Hospital of Wisconsin (Milwaukee, WI). With vigorous hydration of 45 ml/kg isotonic fluid in the emergency room, her hematocrit dropped to 18. Blood was ordered, a nasogastric tube was placed while the patient was in the emergency room, and saline lavage yielded only scantily blood-stained fluid. A tentative diagnosis of gastric ulcer was made, and she was transported to the operating room for urgent endoscopy without any further routine workup or radiography. Transfusion of 250 ml cross-matched packed erythrocytes was begun in the preoperative area. Suddenly, the child sat up and began to vomit bright red blood profusely. She was rushed to the operating room, and resuscitation with blood and fluids was intensified. Throughout, the child was conscious and followed commands.

A rapid-sequence induction with intravenous ketamine (60 mg) and succinylcholine (40 mg) was performed. The trachea was intubated with a cuffed 6.0-mm-ID endotracheal tube. Midazolam (2 mg) and rocuronium (50 mg) were administered, and the patient underwent

ventilation with 100% oxygen. The patient continued to lose massive amounts of blood from the mouth, and despite ongoing fluid resuscitation through two peripheral intravenous cannulae (22 and 20 gauge) in the left and right arms, she sustained a cardiac arrest within minutes. Central pulses were absent, the pulse oximeter failed, and end-tidal carbon dioxide values decreased to single digits, while the electrocardiogram showed a sinus tachycardia of 180 beats/min. Chest compressions were begun and were continued for about 5 min. During 17 min of resuscitation, 900 mg CaCl₂, 1 mg epinephrine, 750 ml packed erythrocytes, and 500 ml albumin, 5%, were administered, and an epinephrine infusion (0.1-1.0 $\mu\text{g} \cdot \text{kg}^{-1} \cdot \text{min}^{-1}$) was started. These measures resulted in a return of faint femoral pulses and end-tidal carbon dioxide but also in an increase in oral blood loss, which made endoscopy impossible. An emergency laparotomy was performed with the presumption that the bleeding source was gastroduodenal.

The stomach was massively distended with clotted and fresh blood. No source of gastric bleeding was found, but there was a steady flow of bright red blood from the esophagus. After attempted esophagoscopy, a dark, stained 25-cent coin was found in the opened stomach. The esophageal bleeding remained brisk, and a pumping bleeding source was noticed by the endoscopist in the mid esophagus about 18 cm from the incisors. A 24-French Foley balloon catheter was introduced retrograde by the surgeon, and after 15-ml balloon inflation, the bleeding markedly decreased. This measure allowed the anesthesia team to catch up with the blood loss and allowed the surgical team to establish invasive monitoring. The epinephrine infusion was stopped. Another surgical attempt to locate the source of bleeding by deflation of the Foley catheter resulted in very brisk rebleeding and was abandoned.

The cardiothoracic surgeons were consulted. They made a presumptive diagnosis of an AEF and approached the aorta *via* left thoracotomy. Extensive friable granulation tissue was encountered between the esophagus and the distal aortic arch. To better visualize the operating field without compromising distal perfusion during aortic cross-clamping, the patient was placed on partial cardiopulmonary bypass with cannulae in the left atrium and the mid descending thoracic aorta. Throughout the whole bypass procedure, the heart continued to beat, providing perfusion to the cerebral and coronary circulations. The patient was fully heparinized (14,000 IU) and was kept mildly hypothermic (34-35°C). Distal perfusion pressure was monitored by a surgically placed femoral arterial line, and proximal pressures were obtained noninvasively by oscillotometry. A right radial arterial line would have been ideal during partial bypass, but could not be placed. A left radial arterial line was easily placed but was significantly blunted during aortic cross-clamping. A 4-mm AEF was found 0.5 cm distal to the left subclavian artery. The fistula was isolated between clamps placed on the mid transverse arch, *i.e.*, between the left carotid and subclavian arteries, and the descending thoracic aorta, respectively. The esophagus was closed primarily using a small segment of aortic wall, which was left attached to the esophagus. The diseased segment of aorta was replaced with a 14-mm Dacron graft, presoaked in antibiotic solution. Aortic clamp time was 35 min, and partial bypass time was 40 min. The patient was weaned from partial bypass without difficulty. After closure of the thorax, a feeding gastrostomy tube was placed, and the abdomen was closed. The total volume of fluids and blood products infused was 3,000 ml packed erythrocytes, 500 ml fresh frozen plasma, 3 four-donor units (= 150 ml) of platelets,

* Associate Professor, † Research Fellow, Department of Anesthesiology, ‡ Associate Professor, Department of Anesthesiology, Division of Pediatric Surgery, § Assistant Professor, Division of Cardiothoracic Surgery, || Assistant Professor, Department of Pediatrics, # Clinical Professor, Division of Cardiothoracic Surgery, Medical College of Wisconsin.

Received from the Sections of Pediatric Anesthesia, Pediatric Surgery, and Pediatrics, Children's Hospital of Wisconsin, Milwaukee, Wisconsin, and the Department of Anesthesiology and Anesthesia Research Service, Medical College of Wisconsin, Milwaukee, Wisconsin. Submitted for publication December 28, 2000. Accepted for publication April 2, 2001. Support was provided solely from institutional and/or departmental sources.

Address reprint requests to Dr. Stuth: Children's Hospital of Wisconsin, Section of Pediatric Anesthesia, Milwaukee, Wisconsin 53226. Address electronic mail to: estuth@mcw.edu. Individual article reprints may be purchased through the Journal Web site, www.anesthesiology.org.

1,500 ml albumin (5%), and 4,000 ml lactated Ringer's solution, totaling an estimated blood loss replacement of 2.5 blood volumes. The patient underwent extubation on postoperative day 2 and was discharged home after 2 weeks. Follow-up clinical examination and esophagography 3 months later were unremarkable.

Discussion

An AEF is a rare cause of bleeding in the upper gastrointestinal tract. The few cases reported in children were associated with congenital vascular rings or foreign body ingestion.³⁻⁵ All reported children with AEF after foreign body ingestion died except for an 8-month-old child in which an extended laparotomy and esophagotomy were performed until the bleeding site was found and manually compressed.⁵ In our case, the AEF was diagnosed after gastrotomy, and the bleeding was successfully tamponaded with a Foley catheter. The fistula was then repaired through a left thoracotomy using partial cardiopulmonary bypass.

Foreign body ingestion is common in children and may present with atypical symptoms.³ In many cases, parents report suspicion of foreign body ingestion. However, in this child, the bleeding was attributed to a gastric ulcer, and no specific questions were asked. In addition, chest radiography was omitted in both emergency departments. This case suggests that in the absence of a definite cause, a portable chest radiograph should be obtained routinely and early in a child with upper gastrointestinal bleeding. It does not delay further therapy and might yield unexpected results. Placement of a nasogastric tube with the significant risk of dislodging the foreign body and causing additional bleeding clearly would have been avoided.

In the current case, the sequence of events was determined by the profuse bleeding that started in the preoperative area and demanded vigorous fluid resuscitation. We assume that the bleeding slowed down during the arrest period because of tamponade or closure of the AEF with clot or surrounding tissue. After the source of the bleeding was identified, balloon tamponade of the

esophagus with a Foley catheter proved to be an effective method to tamponade the bleeding site and allowed us to reestablish an adequate circulating blood volume. Esophageal compression, usually with a Sengstaken-Blakemore tube, has been described in adults for the same purpose and allowed for surgery to close the fistula.^{1,6}

Had radiography been performed in this child, the knowledge of a foreign body in the esophagus, together with hematemesis, could have led to the tentative diagnosis of vascular erosion. However, given the rare occurrence of AEF, the most likely next step would have been a rigid esophagoscopy and an attempt to remove the coin. This probably would have led to rebleeding with possible exsanguination as has been described by Gilchrist *et al.*³ Placement of a balloon catheter from above may have also tamponaded such bleeding. Esophageal balloon tamponade seems to offer the best chance to stop massive arterial bleeding from an AEF so that surgical repair can be performed.

In summary, we report the successful resuscitation and recovery of a child with a previously undiagnosed aorto-esophageal fistula. Despite initial exsanguination, massive volume resuscitation, cardiac massage, and esophageal balloon tamponade allowed temporary cardiovascular stabilization of the child and the performance of a definitive surgical repair.

References

1. Amin S, Luketich J, Wald A: Aorto-esophageal fistula: Case report and review of the literature. *Dig Dis Sci* 1998; 43:1665-71
2. Hollander JE, Quick G: Aorto-esophageal fistula: A comprehensive review of the literature. *Am J Med* 1991; 91:279-86
3. Gilchrist BF, Valerie EP, Nguyen M, Coren C, Klotz D, Ramenofsky ML: Pearls and perils in the management of prolonged, peculiar, penetrating esophageal foreign bodies in children. *J Pediatr Surg* 1997; 32:1429-31
4. Sigalet DL, Laberge JM, DiLorenzo M, Adolph V, Nguyen LT, Youssef S, Guttman FM: Aorto-esophageal fistula: Congenital and acquired causes. *J Pediatr Surg* 1994; 29:1212-4
5. McComas BC, van Miles P, Katz BE: Successful salvage of an 8-month-old child with an aorto-esophageal fistula. *J Pediatr Surg* 1991; 26:1394-5
6. Heckstall RL, Hollander JE: Aorto-esophageal fistula: Recognition and diagnosis in the emergency department. *Ann Emerg Med* 1998; 32:502-5

Sequential Compression Devices Can Cause Erroneous Cardiac Output Measurements

Seda B. Akinci, M.D.,* Peter Pronovost, M.D., Ph.D.,† Todd Dorman, M.D., F.C.C.M.‡

LOWER limb pneumatic compression devices are recommended to prevent venous thromboembolism in many intensive care unit patients.¹ These pneumatic stockings increase lower limb venous return, causing acute but transient decrease in pulmonary artery blood temperature. Although they increased the variability between individual measurements, the use of these stockings was reported not to affect the accuracy of thermodilution cardiac output (CO) measurements made using 10 ml room temperature injectate.^{2,3}

We present a case in which the use of a pneumatic sequential compression device affected CO measurements, thereby delaying decision making, misguiding therapy, and increasing resource use.

Case Report

A 70-yr-old man was transferred emergently to the surgical intensive care unit from an outside hospital for management of a perforated esophagus secondary to dilatation for a peptic stricture. He had a significant medical history for hypertension and for coronary artery disease with coronary artery bypass grafting 21 and 11 yr previously. All saphenous vein grafts and native vessels were occluded. His internal mammary graft was his only patent cardiac vessel. His left ventricular function was estimated to be normal (57%). He had poor exercise tolerance and frequent angina; his medications included atenolol, hydrochlorothiazide, nitroglycerine, and furosemide.

A sequential compression device (SCD) with long sleeves with 45 mmHg (Sequel model 7325; Kendall Co., Mansfield, MA) was applied to each leg as part of routine practice for admission to our surgical intensive care unit.

He was taken to the operating room for a diverting cervical esophagostomy, exploratory laparotomy, and reduction of diaphragmatic hernia as well as placement of a gastrostomy tube. His intraoperative course was uneventful. He arrived back in the intensive care unit intubated, and mechanical ventilation was started.

During the next 6 h, a significant capillary leak developed in the patient, requiring large-volume crystalloid resuscitation (total intake – total output = +6 l), after which we decided to place a pulmonary artery catheter to assist with fluid management. A pulmonary artery thermodilution catheter (PAC; Baxter Swan Ganz ref. 131HF7, ther-

modilution catheter with antimicrobial coating (AMC) thromboshield-antimicrobial heparin coating 7F; Baxter Healthcare Corp., Edwards Critical Care Division, Irvine, CA) was placed uneventfully by rewiring of the previously placed right internal jugular central venous catheter. The PAC was connected to the CO module (7200 TRAM AR model No. S7200 Tram Module) of the monitor (series 7010 monitors; Marquette Electronics Inc., Milwaukee, WI).

After placement of the PAC, the patient had an arterial blood pressure of 91/46 mmHg, a heart rate of 100 beats/min, a pulmonary artery pressure of 39/20 mmHg, a central venous pressure of 6 mmHg, a temperature of 38.8°C, a CO of 3.7 l/min with an index of 1.8, a pulmonary artery wedge pressure of 6 mmHg, a stroke volume of 37 ml, and a systemic vascular resistance of $1,189 \text{ dyn} \cdot \text{s}^{-1} \cdot \text{cm}^5$.

The effect of further fluid resuscitation and vasoactive support on CO could not be assessed because the nursing staff reported variability of the CO measurements. The individual CO measurements varied between 1.8 and 10.4 l/min. Different physicians and nurses saw erratic waveforms with multiple attempts to measure CO. Without infusing injectate, the bedside cardiac monitor showed cycling output waveforms that varied between 3.5 and 5.0 l/min. Despite changing the monitor, changing the PAC, and having a biomedical engineer investigate the monitor, the problem persisted.

During this struggle with the CO measurements, care for the patient was guided by clinical assessment. After 4 h, the cause of the erratic waveforms was found to be from the cycling of the SCDs. We turned the SCDs off, and CO was measured to be 5.7 l/min with an index of 2.7, stroke volume was 63 ml, systemic vascular resistance was $814 \text{ dyn} \cdot \text{s}^{-1} \cdot \text{cm}^5$ when blood pressure was 100/51 mmHg, heart rate was 90 beats/min, pulmonary artery pressure was 39/22 mmHg, and central venous pressure was 11 mmHg. Core temperature measured by PAC was 38.3°C, and injectate temperature was 24.7°C. The skin of the lower extremities was cool, with a toe temperature of 33.1°C, and the patient had 2+ pitting edema of the lower extremities.

We took several steps to establish a causal relation between SCD compression and the autonomous CO. First, we applied the SCDs to one leg and obtained an output from the CO computer of 5.8 l/min, with a stable baseline and good waveforms. Second, we reapplied the SCDs to two legs again; erratic waveforms and cycling autonomous output from CO computer reoccurred again. Third, when the full-leg SCDs were replaced with calf SCDs, erratic waveforms disappeared. Finally, we reapplied the full-leg SCDs, and the autonomous output CO computer reappeared and varied between 3.5 and 5.3 l/min. The rest of the CO measurements were obtained while the SCDs were temporarily turned off. The patient resolved the inflammatory response and was discharged from the intensive care unit 5 days later.

Discussion

Lower limb pneumatic compression devices are commonly used in intensive care units to prevent venous thromboembolism. We present a patient in whom we believe sequential compression devices caused erroneous CO measurements.

When using a PAC, CO is inversely proportional to the area under the thermodilution curve and is determined by injectate volume, blood temperature, density factor,

* Critical Care Fellow, Department of Anesthesiology and Critical Care Medicine, † Assistant Professor, Departments of Anesthesiology and Critical Care Medicine, Surgery, and Health Policy and Management, ‡ Associate Professor, Departments of Anesthesiology and Critical Care Medicine, Surgery and Medicine, The Johns Hopkins University School of Medicine; joint appointment: Johns Hopkins University School of Nursing.

Received from The Johns Hopkins Medical Institution, Baltimore, Maryland. Submitted for publication December 12, 2000. Accepted for publication April 12, 2001. Supported by the Department of Anesthesiology and Critical Care Medicine, Johns Hopkins School of Medicine, Baltimore, Maryland.

Address reprint requests to Dr. Akinci: Hacettepe University, Department of Anesthesiology, Sıhhiye Ankara, Turkey 06100. Address electronic mail to: sedabanu@yahoo.com. Individual article reprints may be purchased through the Journal Web site, www.anesthesiology.org.

and computation constant. In the current patient, the measure of CO was significantly impacted by the use of SCDs. Given that the thermistor on the PAC measures temperature changes, we hypothesize that the inflation cycle of the compression stockings brought cool blood from the legs into the central circulation, resulting in a decrease in pulmonary artery blood temperature. In this extreme example, because the patient was febrile and edematous with a low stroke volume, the volume of cool blood from the two legs squeezed by the long-sleeve SCD was enough to create a CO waveform and CO calculation by the computer. Neither one-leg SCD nor calf SCD compression produced enough volume to create a CO waveform by itself. We postulate that sepsis and the ensuing volume resuscitation may have resulted in cool extremities and that the patient's low flow state amplified the impact of cool fluid being delivered to the central circulation.

Horiuchi *et al.*² found a larger coefficient of variation on the pulmonary artery pressures when the calf pneumatic compression devices were used. In one patient in whom temperature changes in pulmonary artery blood were compared between the compression device on one or both legs, less temperature change was noted when the device was applied to one leg. They postulated that the larger the amount of cool blood that returns, the greater the variability in temperature. Despite this variation, CO was unaffected by the use of an intermittent compression device. Nonetheless, the variability was

greater when they used room temperature injectate instead of iced injectate. With the higher temperature of injectate, the decrease in pulmonary artery temperature would be less than that observed with ice-cold injectate.²

In the current patient, the impact of the transient decrease in pulmonary artery temperature from the peripheral pooled venous blood was perceived as a new CO curve by the computer. One would also expect that lower stroke volumes would result in less warm blood being ejected from the heart, thus increasing the effect of cool blood being returned from the limbs.³

The use of SCDs is important for preventing deep venous thromboses in critically ill patients and will likely remain a mainstay of patient care in intensive care units. Physicians need to be aware of the potential for full-leg SCDs to impact thermodilution CO measurements and may need to consider temporarily turning SCDs off during CO measurements when these measurements are highly variable.

References

1. Goldhaber SZ: Medical progress: Pulmonary embolism. *N Engl J Med* 1998; 339:93-104
2. Horiuchi K, Johnson R, Weissman C: Influence of lower limb pneumatic compression on pulmonary artery temperature: Effect on cardiac output measurements. *Crit Care Med* 1999; 27:1096-9
3. Hickey R: Pneumatic compression stockings increase the variability of the thermodilution cardiac output measurements: Do they truly affect cardiac output? *Crit Care Med* 1999; 27:1039-41

Anesthesia for Cesarean Delivery in a Patient with an Undiagnosed Traumatic Diaphragmatic Hernia

Cynthia L. Dietrich, D.O.,* Charles E. Smith, M.D., F.R.C.P.C.†

DELAYED diagnosis of traumatic diaphragmatic injuries may result in gastric or intestinal herniation and intestinal obstruction.^{1,2} If the hernia becomes strangulated, ischemia, necrosis, and sepsis may develop. Pulmonary and cardiac complications occur because of compression of the lung and heart by the herniated organs or herniation of organs into the pericardial sac.³⁻⁵ Rarely, perforation of herniated organs may lead to pneumothorax and pneumomediastinum.⁶

Delayed presentation of traumatic diaphragmatic hernia occurs because there are no distinctive symptoms or signs associated with diaphragmatic injuries and because these injuries can be difficult to diagnose without laparotomy, which is usually performed for other acute injuries.⁷ Occasionally, herniation may only begin long after the initial injury, and the hernia may then rapidly enlarge within days or weeks.^{2,8} Increased intraabdominal pressure during the second and third trimesters of pregnancy and during labor may also predispose to herniation and strangulation.⁸ We report a patient with undiagnosed diaphragmatic hernia who required urgent cesarean delivery for nonreassuring fetal status. The diagnosis was first suspected during preanesthetic evaluation of the patient. The postoperative course was complicated by respiratory failure, pericardial tamponade, intestinal ischemia, and sepsis.

* Assistant Professor, † Associate Professor.

Received from the Faculty of Medicine, Case Western Reserve University, Department of Anesthesia, MetroHealth Medical Center, Cleveland, Ohio. Submitted for publication January 31, 2001. Accepted for publication April 16, 2001. Funding for library, photography, and computer services was provided by the Department of Anesthesia, MetroHealth Medical Center.

Address reprint requests to Dr. Smith: Department of Anesthesia, MetroHealth Medical Center, 2500 MetroHealth Drive, Cleveland, Ohio 44124. Address electronic mail to: csmith@metrohealth.org. Individual article reprints may be purchased through the Journal Web site, www.anesthesiology.org.

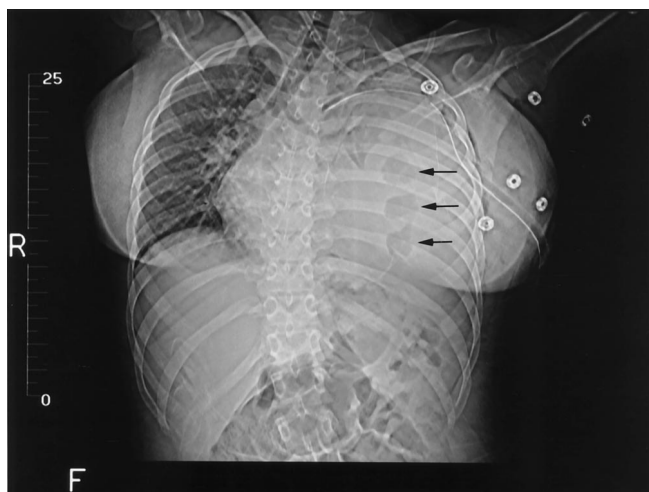

Fig. 1. Supine computed tomography scout film of the chest showing almost complete left lung collapse, mediastinal shift, and tracheal deviation. A chest tube is in place. Note the presence of air within the segmental loops of bowel (arrows).

Case Report

A 19-yr-old gravida 3 para 0 woman, 36½ weeks' gestational age in active labor, was transferred to our institution with a 2-day history of severe left upper quadrant pain and dyspnea. She had sustained a stab wound to the left side of the chest 3 yr ago and did not require surgical intervention. Past history included appendectomy and asthma. There had been no asthma exacerbations for the past 2 yr, and she was not taking daily asthma medications. Her previous two pregnancies had ended in miscarriages at 5 months (3 yr previously) and at 4 months (1 yr previously), respectively. Medications were prenatal vitamins and iron.

Blood pressure was 121/83 mmHg, pulse was 131 beats/min, respiration was 28 breaths/min, temperature was 36.7°C, oxygen saturation was 96% on 4 l O₂ via nasal cannula. Breath sounds were absent on the left side, and the trachea was deviated to the right. There was no wheezing. Cardiovascular examination showed tachycardia, and the point of maximal impulse was displaced to the right. Fetal heart rate was decreased with late decelerations. The patient was transferred to the operating room for urgent cesarean delivery. Left-sided uterine displacement was performed. However, because of concerns for maternal safety, a portable chest radiograph was obtained, which showed total opacification of the left hemithorax with rightward displacement of mediastinal structures.

The membranes were artificially ruptured, and internal fetal heart rate monitoring was instituted. Thoracic and trauma surgery staff were consulted. Meperidine, 25 mg, was administered intravenously, and a left-sided chest tube was inserted using local anesthesia. Approximately 1,200 ml blood-tinged fluid was drained, and clinically, the patient was less dyspneic. Nonreassuring fetal status persisted, and the scalp pH was 7.20. Thirty milliliters sodium citrate was administered orally. Spinal anesthesia was performed with the patient in the sitting position with 12 mg hyperbaric bupivacaine, and a T6 level was obtained. Forty milligrams intravenous ephedrine, in incremental doses, was required to maintain blood pressure between 105/40 and 120/50 mmHg. Heart rate was 130–140 beats/min, and oxygen saturation measured by pulse oximetry (SpO₂) was 97–100% with 10 l O₂/min via a nonrebreathing face mask. A healthy female infant was delivered 4 min after incision. Twenty milligrams intravenous ketamine was required for analgesia during delivery.

Postoperatively, a computed tomography scan of the chest showed a defect in the anterior aspect of the left hemidiaphragm dome, with herniation of bowel and mesentery into the left hemithorax and almost complete left lung collapse (figs. 1 and 2). The patient was

admitted to the intensive care unit. On postoperative day 1, the patient experienced worsening dyspnea and tachypnea and was thought to have pneumonia. The leukocyte count was 22,000, and the hematocrit was 23%. The echocardiogram showed a large pericardial effusion and diastolic right atrial collapse, indicative of hemodynamically significant pericardial tamponade. A subxiphoid pericardiostomy was performed during general anesthesia. Ketamine, 120 mg, and succinylcholine, 100 mg, were used at induction. Isoflurane, 0.4–0.6% inspired, fentanyl, 100 µg, and rocuronium, 50 mg, were used during maintenance. In addition to standard monitors, direct arterial blood pressure monitoring was performed. Two units packed erythrocytes were administered.

After surgery, the patient's trachea remained intubated, and she required treatment for multiple medical problems, including acute respiratory distress syndrome, septicemia, pneumonia, and venous thromboembolism. Blood cultures were positive for Gram-negative organisms. Because of her severe hypoxemia and compromised respiratory status, a decision was made to delay repair of the diaphragmatic hernia. One month later, she underwent left thoracotomy for debridement of necrotic colon, decortication of left lung, primary repair of diaphragmatic hernia, transverse colectomy with anastomosis, tracheostomy, and gastrostomy tube placement. Postoperatively, acute pancreatitis developed in the patient. She was discharged to rehabilitation care 3 months after her cesarean delivery. Two months later, her tracheostomy and gastrostomy tubes were removed, and she was discharged home, independent for activities of daily living and able to care for her healthy child.

Discussion

Diaphragmatic injuries occur frequently after penetrating thoracoabdominal trauma, with an incidence of 13–19%.^{9–11} The majority of injuries are located near the site of entrance to the chest wall, and the wound size averages 2–4 cm.^{10,12} Diaphragmatic rupture after blunt trauma (e.g., motor vehicle accident) is less common, with an incidence of approximately 5%.¹³ Because the diaphragm is in constant motion, spontaneous healing after injury is unlikely. In fact, most defects tend to

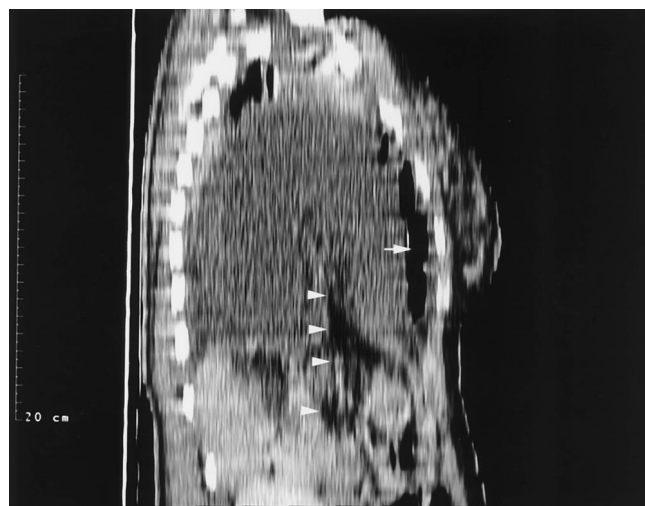


Fig. 2. Sagittal reconstruction through the mid left hemithorax. Note the herniated loop of bowel, with a fluid level, extending almost to the lung apex (arrow). There is mesenteric fat extending from the abdomen, through the diaphragm, and into the chest (arrowheads). There is a small amount of aerated lung superiorly.

enlarge or result in strangulation of herniated organs or portions of omentum. The colon is the most commonly herniated viscus, as in the current patient. The stomach, omentum, small bowel, and liver may also herniate through the traumatic rupture, depending on the anatomic location of the tear.

After diagnosis, surgical treatment is required to avoid strangulation of herniated organs.^{8,13} During pregnancy and labor, there is increased risk of herniation and strangulation because the enlarged uterus forces increasing amounts of abdominal contents into the chest. Any patient with abdominal viscera occupying a large portion of the chest must be considered at risk of regurgitation, aspiration, hypoxemia, and hemodynamic compromise.¹⁴ Tracheal intubation difficulties may also be encountered because of mediastinal shift and deviation of the trachea. The mortality rate of chronic incarcerated diaphragmatic hernia can be as high as 20%, whereas that of strangulated hernias may approach 85%.^{10,15}

Spinal anesthesia was chosen to minimize the risk of aspiration associated with general anesthesia. The use of regional anesthesia also helps to minimize the risk of maternal hypoxemia caused by the collapsed lung and avoids the need for tracheal intubation and airway instrumentation, which might precipitate bronchospasm, given the history of asthma. Nonetheless, it is recognized that respiratory compromise can still occur with regional anesthesia, especially with high sensory levels, because of blockade of the muscles of respiration and reduction of the inspiratory capacity and expiratory reserve volume.¹⁶

Use of general anesthesia and positive-pressure ventilation may be advantageous in patients with traumatic diaphragmatic hernia to expand the atelectatic lung, increase functional residual capacity, and deliver high concentrations of oxygen. However, large tidal volumes and high peak airway pressures are not recommended because of the risk of barotrauma to the nonaffected lung. Moreover, large tidal volumes and high airway pressures may decrease venous return and cardiac output with resultant maternal hypotension and diminished uterine blood flow and placental perfusion. Nitrous oxide is best avoided in situations of bowel obstruction and strangulation because it can expand the air-filled bowel and aggravate the mediastinal shift.

Pericardial tamponade has previously been associated with traumatic diaphragmatic hernia due to herniation of bowel into the pericardial sac⁵ and due to accumulation of fluid within the pericardial space. Echocardiography is especially useful in these situations, as demonstrated by Colliver *et al.*⁴ and Fleyfel *et al.*¹⁷ Echocardiography can also be used to examine trauma patients rapidly with regard to cardiac anatomy and function (*e.g.*, blunt or penetrating cardiac injury), as well as the integrity of the thoracic aorta.^{18,19} Anesthetic goals for patients with acute tamponade include maintaining myocardial con-

tractility, cardiac preload, heart rate, and systemic vascular resistance.²⁰ Ketamine remains an excellent choice for induction of anesthesia in these situations. Ketamine produces sympathetic nervous system stimulation with increased heart rate, blood pressure, and cardiac output. However, ketamine may cause direct myocardial depression and result in hypotension and decreased cardiac output if catecholamine stores are depleted or if there is exhaustion of sympathetic system compensatory mechanisms. Pericardiocentesis performed with local anesthesia before induction of general anesthesia was not an option in the current patient because of the presence of herniated bowel within the mediastinum.

The timing of surgical interventions was clearly of major importance in this patient. Delay in repair of the diaphragmatic hernia was chosen because of acute respiratory distress syndrome and sepsis, thought to be caused by pneumonia and not necrotic bowel. Surgery was performed as soon as it was recognized that her bowel was ischemic. In retrospect, there was a window of approximately 24 h postpartum when she could have undergone thoracotomy and laparotomy before the onset of acute respiratory distress syndrome. After acute respiratory distress syndrome developed, it was believed that she would not survive surgical repair of the diaphragmatic hernia.

In summary, we present a case of a delayed diagnosis of traumatic diaphragmatic hernia in a pregnant patient. The importance of the preanesthetic evaluation, including history and physical examination, is emphasized. A high index of suspicion for diaphragmatic hernia is necessary in any obstetric patient with a history of penetrating thoracoabdominal trauma. The increased intraabdominal pressures during pregnancy and labor can predispose to strangulation, which is associated with significant morbidity and mortality. Radiographic evaluation of the chest, including chest computed tomography, are diagnostic.

The authors thank Leroy Dierker, M.D. (Department of Obstetrics and Gynecology, MetroHealth Medical Center [MHMC], Cleveland, OH); Norman Snow, M.D. (Division of Thoracic Surgery, MHMC); William Fallon, M.D., and Charles Yowler, M.D. (Division of Trauma Surgery, MHMC), for managing the obstetrical and surgical issues; Harris Freed, M.D. (Department of Radiology, MHMC), for radiologic interpretation; and all MetroHealth personnel involved in the care of the patient and her child.

References

- Schulman A, van Gelderen F: Bowel herniation through the torn diaphragm, I: Gastric herniation. *Abdom Imaging* 1996; 21:395-9
- Schulman A, van Gelderen F: Bowel herniation through the torn diaphragm, II: Intestinal herniation. *Abdom Imaging* 1996; 21:400-3
- D'Cruz IA, Sugathan P: Compression of right atrium by traumatic diaphragmatic hernia. *Am Heart J* 1997; 133:380-3
- Colliver C, Oller DW, Rose G, Brewer D: Traumatic intrapericardial diaphragmatic hernia diagnosed by echocardiography. *J Trauma* 1997; 42:115-7
- Barker JA, Gavant ML, Hughes CB: Posttraumatic intrapericardial diaphragmatic hernia. *Am J Roentgenol* 1997; 169:315-6
- Lacayo L, Taveras JM III, Sosa N, Ratzan KR: Tension fecal pneumothorax in a postpartum patient. *Chest* 1993; 103:950-1
- Nagy KK, Barrett J: Diaphragm, *The Textbook of Penetrating Trauma*.

Edited by Ivatury RR, Cayten CG. Baltimore, Williams & Wilkins, 1996, pp 564-70

8. Dudley AG, Teaford H, Gatewood TS Jr: Delayed traumatic rupture of the diaphragm in pregnancy. *Obstet Gynecol* 1979; 53(suppl 3):258-278

9. Mariadason JG, Parsa MH, Ayuyao A, Freeman HP: Management of stab wounds to the thoracoabdominal region: A clinical approach. *Ann Surg* 1988; 207:335-40

10. Madden MR, Paull DE, Finkelstein JL, Goodwin CW, Marzulli V, Yurt RW, Shires GT: Occult diaphragmatic injury from stab wounds to the lower chest and abdomen. *J Trauma* 1989; 29:292-8

11. Moore JB, Moore EE, Thompson JS: Abdominal injuries associated with penetrating trauma in the lower chest. *Am J Surg* 1980; 140:724-30

12. Adamthwaite DN: Penetrating injuries of the diaphragm. *Injury* 1982; 14:151-8

13. Barnett PS, Van Dongen LGR, Bremner CG: Traumatic diaphragmatic hernia presenting in pregnancy. *S Afr Med J* 1979; 55:94-5

14. Katz RI, Belenker SL, Poppers PJ: Intraoperative management of a patient

with a chronic, previously undiagnosed traumatic diaphragmatic hernia. *J Clin Anesth* 1998; 10:506-9

15. Saber WL, Moore EE, Hopeman AR, Aragon WE: Delayed presentation of traumatic diaphragmatic hernia. *J Emerg Med* 1986; 4:1-7

16. Freund FG, Bonica JJ, Ward RJ, Akamatsu TJ, Kennedy WF Jr: Ventilatory reserve and level of motor block during high spinal and epidural anesthesia. *ANESTHESIOLOGY* 1967; 28:834-7

17. Fleifel M, Ferreira JF, Gonzalez de Linares H, Merlier O, Harchaoui A: Cardiac tamponade after intrapericardial diaphragmatic hernia. *Br J Anaesth* 1994; 73:249-51

18. Frazee RC, Mucha P, Farnell MB, Miller FA: Objective evaluation of blunt cardiac trauma. *J Trauma* 1986; 26:510-19

19. Goarin JP, Cluzel P, Gosgnach M, Lamine K, Coriat P, Riou B: Evaluation of transesophageal echocardiography for diagnosis of traumatic aortic injury. *ANESTHESIOLOGY* 2000; 93:1373-7

20. Stoelting RK, Dierdorf SF: *Anesthesia and Co-Existing Disease*, 3rd edition. New York, Churchill Livingstone, 1993, pp 107-12

Anesthesiology 2001; 95:1031-3

© 2001 American Society of Anesthesiologists, Inc. Lippincott Williams & Wilkins, Inc.

Spinal-Epidural Hematoma following Epidural Anesthesia in the Presence of Antiplatelet and Heparin Therapy

Rainer J. Litz, M.D.,* Matthias Hübler, M.D.,† Thea Koch, M.D.,‡ D. Michael Albrecht, M.D.§

ANTIPLATELET drugs are widely used in various categories of patients¹; therefore, knowledge of their impact on coagulation is important for the patients' perioperative care. The American Society of Regional Anesthesia and Pain Medicine does not consider antiplatelet drugs, by themselves, as risk factors for the development of spinal hematoma in patients having neuraxial blocks, but concurrent use of other medications that affect clotting mechanisms may increase the risk of bleeding complications.^{2,3} We report a case of an epidural hematoma in a patient to whom low-molecular-weight heparin (LMWH) was administered perioperatively as prophylaxis against development of venous thromboembolism and who additionally had taken oral ibuprofen for pain relief on her own.

Case Report

A 63-yr-old woman (weight, 75 kg; height, 165 cm) with American Society of Anesthesiologists physical status III presented for reimplantation of a prosthesis of the right knee. One year previously, the prosthetic joint had been removed because of an infection. At this time, the patient also had spondylodiscitis of the lumbar vertebrae 4 and 5 and of the thoracic vertebra 10 and a paravertebral abscess. Clinically and radiologically, the patient had recovered from this complication. The patient's other significant medical history included an ischemic heart disease of grade II (classification of angina of the

Canadian Cardiovascular Society), allergies to several antibiotics, and arthritic pain of both shoulders. Her preoperative oral medications included 5 mg propranolol twice daily and 150 mg ranitidine once daily. Additionally, one subcutaneous injection of LMWH (nadroparin, 3,800 IU/day) was administered to the patient as a prophylactic antithrombotic treatment. Preoperatively, the activated partial thromboplastin time (PTT) was 33 s (normal range, 30-40 s), the prothrombin time (PT) was 84% (normal range, 70-120%), and the International Normalized Ratio (INR) was 1.01 (therapeutic level, 2-4.5). The platelet count was $151 \times 10^9/l$, at the lower limit of the normal range ($150 \times 10^9/l$ - $400 \times 10^9/l$).

On the day of surgery, the patient did not receive the subcutaneous injection of LMWH, the last dose of which had been administered 12 h previously. She was taken to the operating room, and an indwelling epidural catheter *via* an 18-gauge Tuohy-type needle (Medimex Holfeld, Hamburg, Germany) was placed at the L3-L4 interspace using the "loss-of-resistance" technique. Epidural puncture and insertion of the catheter were uneventful, and no blood or spinal fluid were observed. A test dose of 4 ml bupivacaine, 0.5%, was injected. The block was then extended up to the T6 dermatome using 0.5% bupivacaine. General anesthesia was induced, the trachea was intubated, and surgery was performed with a combined regional-general anesthesia. At the end of surgery, the tracheal tube was removed. The patient was awake and free of pain. The sensory level of anesthesia reached T9, and motor block was Bromage scale 2. After reversal of the motor block, a continuous epidural infusion of 0.25% bupivacaine (8 ml/h) was initiated. Thromboprophylactic treatment with LMWH was reestablished 6 h after the end of surgery. Eighteen hours later, the patient reported pain of increasing intensity at the site of the surgical incisions and back pain. The epidural infusion rate was increased to 12 ml/h, and two boluses of 12 ml bupivacaine, 0.25%, were administered, without yielding a sufficient level of analgesia. Additionally, she received 400 mg ibuprofen rectally for the back pain, which decreased in intensity afterward. The epidural bolus administered after this treatment was painful during injection. Therefore, the epidural infusion was stopped and the catheter was removed approximately 7 h after the second postoperative LMWH administration. At this time, the coagulation parameters of activated partial thromboplastin time, International Normalized Ratio, and prothrombin time were within normal ranges. The platelet count was $118 \times 10^9/l$. After catheter removal, the patient received patient-controlled intravenous analgesia using piritramid.

Ten hours after removal of the epidural catheter, the intensity of the back pain increased again, and voiding difficulties developed. Neuro-

* Staff Anesthesiologist, † Resident, ‡ Professor of Anesthesiology, § Professor and Chairman.

Received from the Department of Anesthesiology and Intensive Care Medicine, Carl-Gustav-Carus University Hospital, Dresden, Germany. Submitted for publication February 5, 2001. Accepted for publication April 16, 2001. Support was provided solely from institutional and/or departmental sources. Presented at the German Annual Meeting of Anaesthesiologists (DAK), Wiesbaden, Germany, May 5-8, 1999.

Address reprint requests to: Dr. Hübler: Department of Anesthesiology and Intensive Care Medicine, Carl Gustav Carus University Hospital, Fetscherstr. 74, 01307 Dresden, Germany. Address electronic mail to: matthias.huebler@mailbox.tu-dresden.de. Individual article reprints may be purchased through the Journal Web site, www.anesthesiology.org.

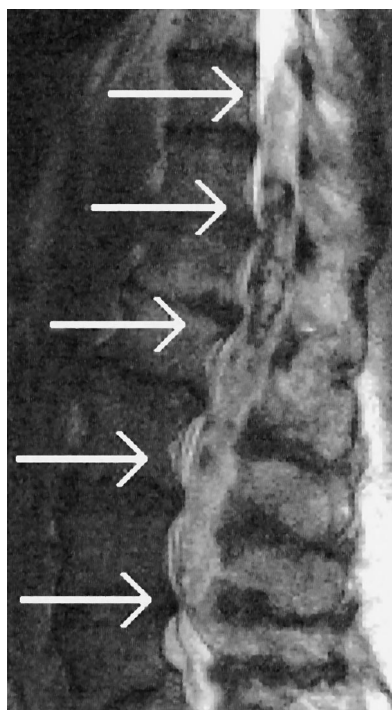


Fig. 1. Sagittal magnetic resonance image showing the large extension of the hematoma, as well as its heterogeneity.

logic examination revealed decreased muscular strength in both lower limbs and decreased sensation up to the dermatome L1. A magnetic resonance image revealed a spinal-epidural hematoma extending from T10 to L4, with an intradural extension in the caudal section (figs. 1 and 2). Emergency decompressive surgery was performed 6 h after the first neurologic symptoms had been noticed. The intraoperative site showed a partially organized as well as a fresh hematoma. There was no evidence of neoplastic changes or vascular malformations. Postoperatively, the patient recovered slowly from her neurologic deficiencies. Control magnetic resonance imaging 5 days later showed a small, infarcted area within the spinal cord at the level of T10. In a detailed interview, during which the patient was asked about specific drugs taken preoperatively, she mentioned that she had taken 500 mg ibuprofen four times daily on her own for her arthritic pain and that she had taken the last dose approximately 10 h before surgery. Four weeks after the event, muscular strength and sensation of the right leg had recovered. A discrete muscular weakness of the left leg with an area of hypesthesia at the foot persisted for 1 yr.

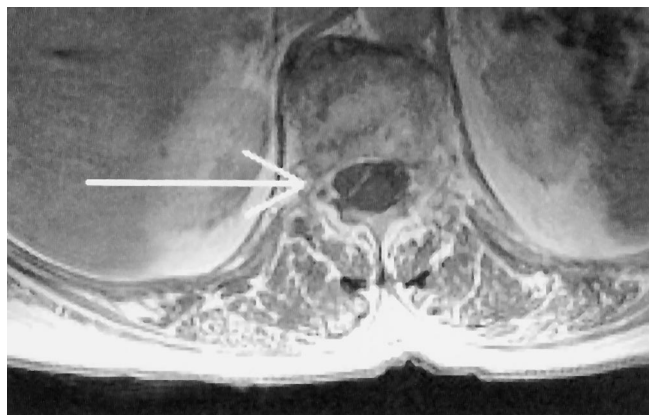

Fig. 2. Axial magnetic resonance image showing the hematoma.

Discussion

There are four major classes of antiplatelet drugs: (1) cyclooxygenase inhibitors (*e.g.*, acetylsalicylic acid [ASA] and nonsteroidal antiinflammatory drugs [NSAIDs]), (2) selective adenosine diphosphate antagonists (*e.g.*, ticlopidine), (3) direct thrombin inhibitors (*e.g.*, hirudin), and (4) platelet glycoprotein IIb and IIIa inhibitors (*e.g.*, tirofiban). Most cases of spinal-epidural hematoma have been reported in patients who are receiving some kind of anticoagulation therapy or who have an otherwise compromised coagulation.⁴⁻⁶ Studies that investigated the use of central neuraxial block in the presence of an antiplatelet treatment with ASA or NSAIDs found no increased risk for spinal bleeding.^{3,7} Although case reports of spinal bleeding in the presence of antiplatelet drugs are sparse,⁸⁻¹⁰ the topic is still controversial. Cyclooxygenase inhibitors acetylate the platelet enzyme cyclooxygenase, which is essential for the biosynthesis of thromboxane A₂. Thromboxane A₂ itself is a potent activator of platelet aggregation and adhesion. The acetylation caused by ASA is irreversible; therefore, even a low dose of ASA (75–325 mg daily) compromises platelet function until a sufficient number of new platelets have been released from the bone marrow.¹¹ However, the acetylation caused by NSAIDs is reversible and lasts for 1–3 days. Cronberg *et al.*¹² demonstrated that the different NSAIDs impair platelet function similarly but that the duration of impairment varies. Ibuprofen (10–12 mg/kg administered once) had a weak but definite effect on the second wave of aggregation, lasting up to 1 day. Preoperatively, the current patient took a much higher dose (27 mg · kg⁻¹ · 24 h⁻¹), and the platelet count at the time of catheter placement was near the lower limit of the normal range. Therefore, the effects of ibuprofen on platelet function were probably stronger and lasted longer. Also, the presumed single dose of ibuprofen administered later for back pain eventually contributed to an impaired thrombocytes function. In addition, the platelet count decreased after surgery, and the patient received two subcutaneous injections of LMWH before catheter removal. Because the subcutaneous blood flow varies interindividually and intraindividually, the patient response to subcutaneous heparin may be difficult to predict; therefore, an intermittently therapeutic anticoagulation cannot be excluded. Altogether, a clotting disturbance likely occurred, which was not detectable by conventional coagulation tests. This also explains the unusually large extension of the hematoma,⁵ which reached caudally beyond the puncture site. Whether small malformations of epidural vessels after paravertebral abscess formation and spondylodiscitis might have been a complicating factor remains speculative. The intraoperative finding of a partially organized as well as a fresh epidural hematoma suggests that bleeding was prolonged and occurred, or at least continued, through-

out the postoperative period. It also suggests that not only the placement of the epidural catheter but also its removal may have contributed to the development of the hematoma. Back pain as an early symptom can be absent in the presence of continuous epidural analgesia.⁵ In the current patient, insufficient analgesia was probably the first clinical sign of the hematoma, which blocked the spread of the local anesthetic to the spinal nerve roots. This emphasizes that patients must be monitored closely when analgesic requirements increase, especially because a significant amount of epidurally administered local anesthetic might further compromise local coagulation.¹³

During the past decade, several case reports and reviews discussed the risk factors for development of a spinal or epidural hematoma after central neuraxial blocks.^{4,5,14} Although the technique is considered to be safe when the clotting function is normal, its use in the presence of coagulation disorders, either caused by a preexisting coagulopathy or by a drug-induced impairment of the coagulation, may be dangerous. The German Society of Anaesthesiology and Intensive Care Medicine, contrary to the American Society of Regional Anesthesia and Pain Medicine guidelines, demands a free interval of 1–2 days after the last administration of NSAIDs and at least a 3-day interval without ASA-containing medications before central neuraxial blocks should be performed or epidural catheters should be removed.^{15,16} Our case supports this recommendation and also documents how difficult obtaining a thorough list of all medications used by the patient preoperatively can be after recommendation.

Early diagnosis of a hematoma is crucial for the prognosis, and the current patient eventually recovered without sequelae from the neurologic deficiencies. This case emphasizes that patients should be asked specifically during the preanesthetic visit for additional drugs, not

routinely taken drugs, especially because the number of antiplatelet drugs is increasing steadily.⁹ Also, a routinely performed postanesthetic follow-up after removal of an epidural catheter is mandatory to minimize the risk for detrimental sequelae.

References

1. Antiplatelet Trialists' Collaboration. Collaborative overview of randomised trials of antiplatelet therapy, I: Prevention of death, myocardial infarction, and stroke by prolonged antiplatelet therapy in various categories of patients. Antiplatelet Trialists' Collaboration. *Br Med J* 1994; 308:81–106
2. Urmev WF, Rowlingson J: Do antiplatelet agents contribute to the development of perioperative spinal hematoma? *Reg Anesth Pain Med* 1998; 23:146–51
3. Horlocker TT, Wedel DJ, Schroeder DR, Rose SH, Elliott BA, McGregor DG, Wong GY: Preoperative antiplatelet therapy does not increase the risk of spinal hematoma associated with regional anesthesia. *Anesth Analg* 1995; 80:303–9
4. Vandermeulen EP, Van Aken H, Vermeylen J: Anticoagulants and spinal-epidural anesthesia. *Anesth Analg* 1994; 79:1165–77
5. Schmidt A, Nolte H: Subdural and epidural hematomas following epidural anesthesia: A literature review. *Anaesthesist* 1992; 41:276–84
6. Wulf H, Maier C, Striepling E: Epidural hematoma following epidural catheter anesthesia in thrombocytopenia. *Reg Anaesth* 1988; 11:26–7
7. Haljamae H: Thromboprophylaxis, coagulation disorders, and regional anaesthesia. *Acta Anaesthesiol Scand* 1996; 40:1024–40
8. Gerancher JC, Waterer R, Middleton J: Transient paraparesis after postdural puncture spinal hematoma in a patient receiving ketorolac. *ANESTHESIOLOGY* 1997; 86:490–4
9. Benzon HT, Wong HY, Siddiqui T, Ondra S: Caution in performing epidural injections in patients on several antiplatelet drugs. *ANESTHESIOLOGY* 1999; 91:1558–9
10. Mayumi T, Dohi S: Spinal subarachnoid hematoma after lumbar puncture in a patient receiving antiplatelet therapy. *Anesth Analg* 1983; 62:777–9
11. Schror K: Antiplatelet drugs: A comparative review. *Drugs* 1995; 50:7–28
12. Cronberg S, Wallmark E, Soderberg I: Effect on platelet aggregation of oral administration of 10 non-steroidal analgesics to humans. *Scand J Haematol* 1984; 33:155–9
13. Honemann CW, Lo B, Erera JS, Polanowska-Grabowska R, Gear AR, Durieux M: Local anesthetic effects on TXA2 receptor mediated platelet aggregation using quenched flow aggregometry. *Adv Exp Med Biol* 1999; 469:269–76
14. Horlocker TT, Wedel DJ: Neurologic complications of spinal and epidural anesthesia. *Reg Anesth Pain Med* 2000; 25:83–98
15. Gogarten W, Van Aken H, Wulf H, Klose R, Vandermeulen E, Harenberg J: Regional anaesthesia and thromboembolism prophylaxis/anticoagulation: Guidelines of the German Society of Anaesthesiology and Intensive Care Medicine (DGAI). *Anesthesiol Intensivmed* 1997; 38:623–8
16. Van Aken H, Gogarten W: Abweichende nationale Empfehlungen zur Durchführung von rückenmarksnahen Regionalanästhesieverfahren bei medikamentöser Antikoagulation. Sind die Ergebnisse der Konsensuskonferenz der ASRA direkt auf Europa übertragbar? *Anesthesiol Intensivmed* 1999; 40:62–4

Anaphylaxis Due to Airborne Exposure to Latex in a Primigravida

Gifford V. Eckhout, Jr., M.D.,* Sabry Ayad, M.D.†

LATEX sensitivity in the surgical population has been well-described, including anaphylactic reactions from contact with latex products in the operating suite.¹⁻⁴ The use of powdered latex examination gloves is associated with increased levels of latex particles in the air.^{5,6} Exposure to airborne latex antigen can trigger allergic reactions in sensitized individuals.^{5,7,8} We describe a case of a parturient with known latex sensitivity who had an anaphylactic reaction in the obstetric triage room after unintentional exposure to airborne latex particles. This reaction precipitated fetal distress and the potential need for emergency cesarean delivery.

Case Report

A 32-yr-old gravida 1 para 0 patient at 32 weeks' gestational age presented to the triage room of the obstetric unit for evaluation of possible preterm labor. At the time of her arrival, the obstetric nurse approached the patient while wearing a pair of powdered latex examination gloves (Perry X-AM[®]; Ansell Healthcare Products, Inc., Massillon, OH). Questioning of the patient before physical contact revealed a history of latex allergy. She reported contact dermatitis to latex in the past and had undergone skin-prick testing to latex antigen, the results of which she reported as positive. She had not had a previous life-threatening reaction to latex. In her prenatal visits, she had been treated with latex-safe precautions. The obstetric staff member removed the gloves in the immediate vicinity of the patient at that time. No contact with the patient was made, nor were medications administered. Within several minutes, the patient began to complain of tightness in her chest and dyspnea. As additional staff were summoned, the dyspnea progressed, and audible wheezing was appreciated. A generalized urticarial rash was noted over her face and trunk. Vital signs were obtained, and oxygen delivery *via* face mask, left uterine displacement, and insertion of an intravenous cannula were accomplished. Initial blood pressure was 80/40 mmHg, pulse was 98 beats/min, and respiratory rate was 24 breaths/min. Fetal heart rate was externally assessed by Doppler ultrasonography and showed fetal bradycardia in the range of 80-90 beats/min.

The obstetrician in attendance instituted initial treatment, which consisted of a rapid 500-ml bolus of lactated Ringer's solution, 50 mg diphenhydramine, and 100 mg hydrocortisone acetate intravenously as the obstetric anesthesia team was summoned to the triage room. At the time of our arrival, the patient was hypotensive, with cuff blood pressure

of 78/40 mmHg and persistent fetal bradycardia. Given the patient's history of previous latex allergy, the presumptive diagnosis of anaphylactic reaction caused by accidental exposure to latex antigen was made. Ephedrine, 10 mg intravenously, was administered for treatment of maternal hypotension because of its immediate availability. Because of prolonged fetal bradycardia (approximately 80 beats/min), the patient was immediately transferred to the operating suite for emergent operative delivery of the fetus. Because the operative suite had not been prepared as a latex-safe environment, the patient underwent preoxygenation in the operating room *via* the latex-free anesthesia ventilator bellows. Reexamination of the patient at this time (approximately 10 min after initial symptoms) revealed a blood pressure of 110/55 mmHg, a heart rate of 100 beats/min, and a respiratory rate of 20 breaths/min. Symptomatically, the dyspnea was less pronounced, and reexamination showed the fetal heart rate to be 100 beats/min and increasing. The patient was observed in the operating room for an additional 15-20 min, during which time her vital signs and symptoms of dyspnea and urticaria resolved. She was transferred to a patient room that had been ventilated and prepared as latex-safe, and was subsequently discharged from the hospital later that day. The patient returned several times in the ensuing weeks for obstetric examination without further difficulties. Strict latex-safe precautions were followed for her subsequent care. She subsequently had a spontaneous vaginal delivery, with delivery of a normal term fetus. The patient declined further laboratory investigation of her latex sensitivity because of her previous positive allergy testing.

Discussion

Latex use is ubiquitous in the medical field. The incidence of potentially life-threatening allergic reaction to latex has been increasing since the late 1980s.⁹ Healthcare providers at all levels are aware of the need for exposure avoidance in the care of the latex-allergic patient. Nevertheless, with mandatory implementation of universal precautions for bodily fluid avoidance, latex is still commonly found throughout the hospital environment.

Airborne exposure to latex can lead to systemic reactions in sensitized individuals, including bronchospasm, angioedema, and hypotension. The use of latex examination gloves, in particular powdered gloves, is associated with a measurable increase in airborne latex particles.¹⁰ Anaphylaxis after airborne exposure has been previously reported during inhalational latex challenge testing.¹¹

Systemic anaphylaxis is a potentially life-threatening condition. Symptoms may include flushing, urticaria, bronchospasm, hypotension, and seizures.¹² In the obstetric population, hypotension with anaphylaxis has been associated with poor fetal outcomes, despite maternal recovery.^{12,13}

The management of anaphylaxis in pregnancy consists of maternal resuscitation and close monitoring of the fetal status, with preparation for immediate delivery of

* Staff, Department of General Anesthesiology, The Cleveland Clinic Foundation. † Director of Obstetric Anesthesia and Staff Anesthesiologist, Westgate Medical Anesthesia Group, Incorporated, Fairview Hospital, Cleveland Clinic Health System.

Received from the Department of General Anesthesiology, The Cleveland Clinic Foundation, Cleveland, Ohio, and Westgate Medical Anesthesia Group, Incorporated, Fairview Hospital, Cleveland Clinic Health System, Cleveland, Ohio. Submitted for publication February 16, 2001. Accepted for publication April 16, 2001. Support was provided solely from institutional and/or departmental sources.

Address reprint requests to Dr. Eckhout: Department of General Anesthesiology and Critical Care Medicine/E31, The Cleveland Clinic Foundation, 9500 Euclid Avenue, Cleveland, Ohio 44195. Address electronic mail to: eckhoug@ccf.org. Individual article reprints may be purchased through the Journal Web site, www.anesthesiology.org.

the fetus if compromised. Treatment of the parturient depends on the severity of the reaction and consists of fluid resuscitation and administration of supplemental oxygen, epinephrine, H1 and H2 blockers, and corticosteroids.¹² Support of maternal circulation is mandatory to prevent uteroplacental insufficiency. Epinephrine is the first-line drug in the treatment of anaphylaxis, and its use in this patient was contemplated. In this case, epinephrine was readily available and was used primarily for immediate treatment of maternal hypotension. The use of epinephrine in the obstetric population has raised concerns of decreasing uteroplacental perfusion and worsening of fetal distress¹⁴; however, maternal hypotension in anaphylaxis must be aggressively treated with fluid resuscitation and pressors, including epinephrine for severe reactions.¹⁵

We present a case in which exposure to airborne latex particles triggered an anaphylactic reaction in a primigravida, with resulting fetal distress. The severity of the reaction nearly led to an emergency cesarean delivery in a preterm pregnancy. Our treatment of this patient consisted of support of maternal circulation with intravenous fluids, vasopressors, and oxygen. Preparations for emergent delivery of the fetus with latex-safe precautions were made as ongoing treatment of anaphylaxis was undertaken. The quick resolution of her symptoms after removal of the latex source obviated the need for more aggressive pharmacologic intervention and cesarean delivery. External fetal heart monitoring was instituted to guide the obstetric management of this emergency.

The high risk of anaphylactic reaction to mother and fetus leads us to suggest that a latex-safe environment, particularly in areas where an obstetric patient is initially examined, be provided to avoid unanticipated exposure to latex allergens in the latex-sensitive patient. In addition, medications and equipment to quickly treat allergic reactions in these patients should be readily available.

References

1. Tan BB, Lear JT, Watts J, Jones P, English JSC: Perioperative collapse: prevalence of latex allergy in patients sensitive to anaesthetic agents. *Contact Dermatitis* 1997; 36:47-50
2. Pollard RJ, Layon AJ, Setzer N: Latex allergy in the operating room: Case report and a brief review of the literature. *J Clin Anesth* 1996; 8:161-7
3. Ebo DG, Stevens WJ, DeClerck, LS: Latex anaphylaxis. *Acta Clin Belg* 1995; 50:87-93
4. Kam PCA, Lee MSM, Thompson JF: Latex allergy: An emerging clinical and occupational health problem. *Anaesthesia* 1997; 52:570-5
5. Tomazic VJ, Shampaine EL, Lamanna MS, Withrow TJ, Adkinson NF Jr, Hamilton RG: Cornstarch powder on latex products is an allergen carrier. *J Allergy Clin Immunol* 1994; 93:751-8
6. Page EH, Esswein EJ, Petersen MR, Lewis DM, Bledsoe TA: Natural rubber latex: Glove use, sensitization and airborne and latent dust concentrations at a Denver hospital. *J Occup Environ Med* 2000; 42:613-620
7. Tarlo SM, Sussman G, Contala A, Swanson MC: Control of airborne latex by use of powder-free latex gloves. *J Allergy Clin Immunol* 1994; 93:985-9
8. Masood D, Brown JE, Patterson R, Greenberger PA: Recurrent anaphylaxis due to unrecognized latex hypersensitivity in two healthcare professionals. *Ann Allergy Asthma Immunol* 1995; 74:311-13
9. Floyd PT: Latex allergy update. *J Perianesthesia Nurs* 2000; 15:26-30
10. Baur X, Chen Z, Allmers H: Can a threshold limit value for natural rubber latex airborne allergens be defined? *J Allergy Clin Immunol* 1998; 101(pt 1):24-7
11. Palczynski C, Walusiak J, Ruta U, Gorski P: Occupational allergy to latex: Life threatening reactions in health care workers: Report of three cases. *Int J Occup Med Environ Health* 1997; 10:297-301
12. Gallagher JS: Anaphylaxis in pregnancy. *Obstet Gynecol* 1988; 71:491-3
13. Konno R, Nagase S: Anaphylactic reaction to cefazolin in pregnancy. *J Obstet Gynaecol* 1995; 21:577-9
14. Entman SS, Moise KJ: Anaphylaxis in pregnancy. *South Med J* 1984; 77:402
15. Holzman RS, Latex allergy, an emerging operating room problem. *Anesth Analg* 1993; 76:635-41

Anesthesiology 2001; 95:1035-7

© 2001 American Society of Anesthesiologists, Inc. Lippincott Williams & Wilkins, Inc.

Complete Heart Block during Anesthetic Management in a Patient with Mucopolysaccharidosis Type VII

Yuichiro Toda, M.D.,* Mamoru Takeuchi, M.D.,* Kiyoshi Morita, M.D.,† Tatsuo Iwasaki, M.D.,* Katsunori Oe, M.D.,* Masataka Yokoyama, M.D.,‡ Masahisa Hirakawa, M.D.§

IT is believed that complete heart block is unlikely to occur in patients without preexisting left bundle branch block. We describe the occurrence of complete heart block during attempted placement of a central venous catheter in a child with mucopolysaccharidosis (MPS)

type VII (Sly syndrome) without preexisting left bundle branch block. Numerous reports of anesthesia in patients with MPS have described airway management and respiratory complications. However, cardiac problems during anesthesia in patients with MPS should be considered important because of the possibility of preexisting cardiomyopathy or coronary stenosis.

* Staff Anesthesiologist, † Associate Professor, ‡ Assistant Professor, § Professor and Chairman.

Received from the Department of Anesthesiology and Resuscitology, Okayama University Medical School, Okayama City, Japan. Submitted for publication December 27, 2000. Accepted for publication April 18, 2001. Support was provided solely from institutional and/or departmental sources.

Address reprint requests to Dr. Toda: Department of Anesthesiology and Resuscitology, Okayama University Medical School, 2-5-1, Shikata-Cho, Okayama City, Japan, 700-8558. Address electronic mail to: yuichirotda@mac.com. Individual article reprints may be purchased through the Journal Web site, www.anesthesiology.org.

Case Report

The patient was a 4-yr-old girl with MPS type VII. Patient height and weight were 92 cm and 13 kg, respectively. She was born in the 36th week of pregnancy, and her weight at delivery was 2,552 g. She underwent phototherapy and an exchange blood transfusion for icterus neonatorum and polycythemia. The patient had retarded speech and motor development, gargoyle facies, and hepatosplenomegaly.

Consequently, she was diagnosed with MPS type VII. At the age of 3 yr, echocardiography was performed because of hypertension (blood pressure, 160/90 mmHg), and angiography revealed severe stenosis of the aorta from the descending to the abdominal part, which is called atypical coarctation of the aorta. After a preoperative examination, the child underwent uneventful aortic bypass grafting from the descending to the abdominal part without an intracardiac procedure on January 14, 2000. No difficulty in intubation was encountered. Postoperatively chest radiography revealed pulmonary atelectasis, and the bronchi were often occluded by viscous sputum. Therefore, mechanical ventilation was maintained, and physiatric intervention was performed for 5 days. The patient was discharged from the intensive care unit 7 days later.

On March 14, 2000, when she was 4 yr old, she was readmitted for bone marrow transplantation because of MPS and was scheduled to undergo insertion of a subcutaneously tunneled central venous catheter during general anesthesia. Her blood pressure was 138/72 mmHg, and no abnormal values were observed in routine preoperative blood tests. No abnormalities, including atelectasis, were revealed by preoperative radiography. The electrocardiogram showed left ventricular hypertrophy but did not reveal any conduction defects.

The patient was premedicated with 3 mg oral midazolam 30 min before anesthesia. Her blood pressure and heart rate were 160/76 mmHg and 140 beats/min, measured by cuff and electrocardiograph, respectively, before anesthesia induction. Anesthesia was cautiously induced with 5% sevoflurane and nitrous oxide in 50% oxygen. A peripheral intravenous catheter was placed on the dorsum of the left hand. Systolic blood pressure of approximately 160 mmHg was observed during induction of anesthesia. Anesthesia was maintained with 1% inhaled sevoflurane *via* face mask, with spontaneous assisted ventilation. Oxygen saturation (SpO₂) and expired carbon dioxide (PETCO₂) were continuously measured, and there was no evidence of hypoxia or hypercapnia during the procedure. A Hickman® 7-French dual lumen central venous catheter (C.R. Bard, Salt Lake City, UT) was selected because long-term catheter placement was expected in this patient. The subclavian approach was used after injection of topical lidocaine. The subclavian vein was readily accessible. Thereafter, the guide wire was smoothly inserted and advanced to the superior vena cava during fluoroscopic control. We tried but failed to insert the introducer with vessel dilator because of difficulty negotiating the infraclavicular space. After a while, blood pressure suddenly decreased to 50 mmHg, and heart rate decreased to 65 beats/min. Nitrous oxide and sevoflurane were discontinued, the fraction of inspired oxygen (FiO₂) was increased to 1.0, and 0.2 mg atropine was administered intravenously. Fluoroscopy revealed that the guide wire had entered the right ventricle; thus, it was withdrawn into the superior vena cava. Despite subsequent intravenous atropine administration (total dose, 3 mg) and 4 mg ephedrine administration, the patient's heart rate decreased to 40 beats/min, and blood pressure was not measurable. The electrocardiogram displayed complete heart block. Cardiac compression was initiated, and the trachea was intubated without difficulty. Fifty micrograms epinephrine was administered intravenously, but circulatory collapse continued. Because hypotension and bradycardia had continued for approximately 10 min, resuscitation had been continued all the while. After administration of an additional 50 µg epinephrine, the patient was successfully resuscitated. Blood pressure increased to 170/94 mmHg, and heart rate increased to 108 beats/min. Immediately after resuscitation, arterial blood gas analysis showed a pH of 7.226, an arterial carbon dioxide tension (Paco₂) of 29.1 mmHg, an arterial oxygen tension (PaO₂) of 463.3 mmHg, and a bicarbonate concentration of 11 mM. Sodium bicarbonate was administered for treatment of metabolic acidosis.

Attempts to insert the Hickman® catheter were aborted. A conventional central venous catheter was introduced into the right internal jugular vein without difficulty. No abnormalities, including pneumothorax and hemothorax, were evident from postoperative chest radiography. After the procedure, the patient's trachea remained intu-

bated, and she was subsequently transferred to the intensive care unit. She regained consciousness at the time of her arrival in the intensive care unit, and her trachea was then successfully extubated. The postoperative course was uneventful, and her consciousness level was similar to that observed preoperatively. Postoperative electrocardiography did not show any changes compared with the preoperative tracing.

Discussion

Previous reports¹⁻³ have shown that airway management during anesthesia is important in patients with MPS. However, cardiovascular complications during anesthesia in patients with MPS have been described in only a few reports. Cardiovascular complications should be considered as a potential consequence of valvular insufficiency, cardiomyopathy, and coronary stenosis. Belani *et al.*⁴ described the occurrence of cardiac arrest in two patients with Hurler syndrome. In both cases, autopsy revealed almost complete occlusion of the coronary arteries. Furthermore, Okada *et al.*⁵ reported that infiltration of the cardiac conduction system by gargoyle cells was present at the time of autopsy in patients with MPS.

Sinus bradycardia followed by complete heart block was most likely a consequence of guide wire-induced trauma of the conduction system, including the atrioventricular node, the His bundle, and the right bundle branch. Complete heart block was difficult to reverse because of possibly associated disease in the coronary arteries and the conduction system in the current patient. Eissa and Kvetan⁶ reported a case of complete heart block caused by direct trauma to the His bundle. Sprung *et al.*⁷ described a case of complete heart block during pulmonary artery catheterization. They suggested that the conduction system may have been compromised by ischemia caused by coronary disease. Although it is believed that the risk of complete heart block is higher in patients with left bundle branch block than in patients without this conduction disturbance, Castellanos *et al.*⁸ reported a case of left bundle branch block during right-sided heart catheterization. Therefore, complete heart block may occur in patients without preexisting left bundle branch block. In the current patient, coronary blood flow most likely decreased as a result of hypotension secondary to sinus bradycardia and then complete heart block; this may have been aggravated by coronary narrowing. Additionally, despite descending aortic bypass grafting, hypertension was still present in the patient. This may have led to altered autoregulation such that the decrease in blood pressure noted may have compounded the decrease in coronary blood flow, causing severe ischemia of the gargoyle-infiltrated conduction system. Cautious advancement of the guide wire by more vigilant fluoroscope use would have prevented this morbidity if the guide wire had been prevented from entering the right side of the heart.

In conclusion, we describe the anesthetic management in a child with MPS type VII. Previous reports have emphasized airway precautions. In this report, we alert clinicians to the likelihood of cardiac complications.

References

1. Diaz JH, Belani KG: Perioperative management of children with mucopolysaccharidoses. *Anesth Analg* 1993; 77:1261-70
2. Baines D, Keneally J: Anaesthetic implications of the mucopolysaccharidoses: A fifteen-year experience in a children's hospital. *Anaesth Intens Care* 1983; 11:198-202
3. Herrick IA, Rhine EJ: The mucopolysaccharidoses and anaesthesia: A report of clinical experience. *Can J Anaesth* 1988; 35:67-73
4. Belani KG, Krivit W, Carpenter BLM, Braunlin E, Buckley JJ, Liao JC, Floyd T, Leonard AS, Summers CG, Levin S, Whitley CB: Children with mucopolysaccharidosis: Perioperative care, morbidity, mortality, and new findings. *J Pediatr Surg* 1993; 28:403-10
5. Okada R, Rosenthal IM, Scaravelli G, Lev M: A histopathologic study of the heart in gargoylism. *Arch Path* 1967; 84:20-30
6. Eissa NT, Kvetan V: Guide wire as a cause of complete heart block in patient with preexisting left bundle branch block. *ANESTHESIOLOGY* 1990; 73:772-4
7. Sprung CL, Elser B, Schein RMH, Marcial EH, Schrage BR: Risk of right bundle-branch block and complete heart block during pulmonary artery catheterization. *Crit Care Med* 1989; 17:1-3
8. Castellanos A, Ramirez AV, Mayorga-Cortes A, Pefkaros K, Rozanski JJ, Sprung C, Myerburg RJ: Left fascicular blocks during right-heart catheterization using the Swan-Ganz catheter. *Circulation* 1981; 64:1271-6