

Anesthesiology  
83:1380-1381, 1995  
© 1995 American Society of Anesthesiologists, Inc.  
Lippincott-Raven Publishers

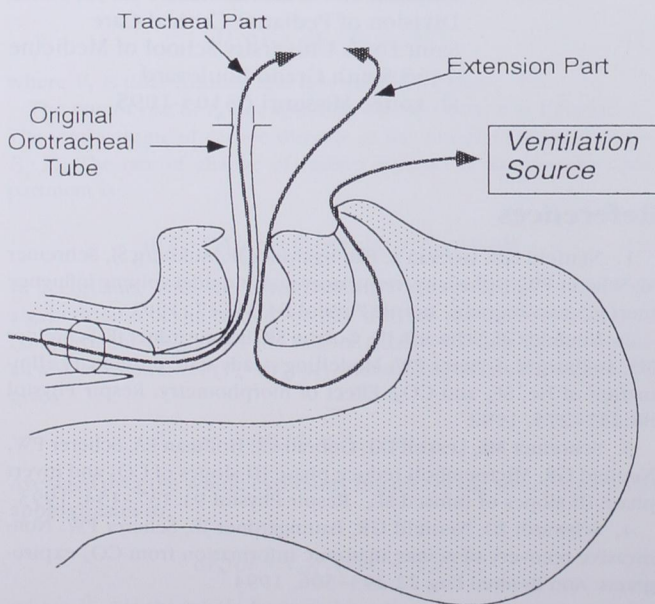
## Oral-to-Nasal Endotracheal Tube Exchange in Patients with Bleeding Esophageal Varices

*To the Editor:*—Several devices have been described for use when an orotracheal tube is changed for a nasotracheal tube in a patient with a compromised airway. Most of these devices rely on direct visualization of the vocal cords. One of the authors (Niimi) has designed, in collaboration with Cook, Inc., an endotracheal tube exchanger (Patil Two-Part Intubation Catheter, Cook, Bloomington, IN) that does not require direct visualization. We describe a case of a patient with actively bleeding esophageal varices in which this newly designed endotracheal tube exchanger was used.

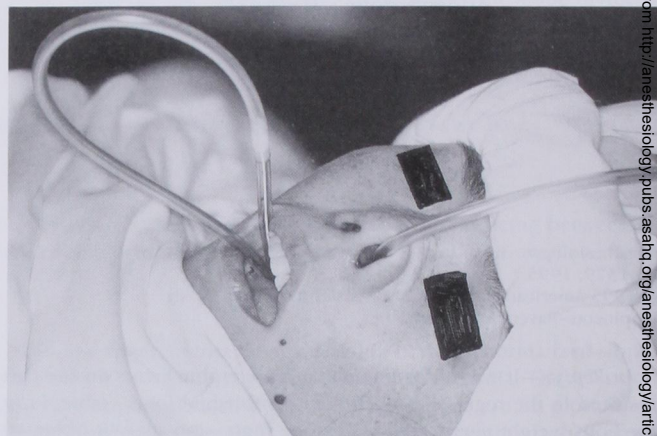A 66-yr-old woman with liver cirrhosis presented with massive bleeding from esophageal varices. The trachea was orally intubated in the emergency room. The endotracheal tube developed a cuff leak, and we were asked to reintubate the trachea nasally to facilitate a hemostasis manipulation. Because the blood in the oropharynx was expected to make direct visualization difficult, we decided to use the endotracheal tube exchanger.

This endotracheal tube exchanger consists of two parts, a tracheal part and an extension part, which can be firmly connected end-to-end. They contain a hollow lumen, which allows jet ventilation.

To use this endotracheal tube exchanger, the patient's left naris was prepared by the application of topical anesthesia and vasoconstrictor. The extension component of an endotracheal tube exchanger was passed through the left naris into the nasopharynx, and its end withdrawn from the mouth with Magill forceps. A tracheal component



**Fig. 1.** The arrangement of the endotracheal tube exchanger.



**Fig. 2.** The original tube was removed, and the extension part was connected to the tracheal part. A loop was formed at the mouth.

was placed through the original orotracheal tube (fig. 1). The 2 cm marking of the tube exchanger was kept at the lips during the endotracheal tube exchange. The original orotracheal tube was removed, and the tracheal part was connected to the extension part (fig. 2), thereby forming a loop at the mouth. The end of the extension part was connected to a jet ventilation source, and jet ventilation was resumed immediately. The nasal end of the extension part was withdrawn slowly from the left naris to straighten the tube exchanger until the loop disappeared. A new endotracheal tube was threaded into the trachea over the whole endotracheal tube exchanger.

Many techniques of oral-to-nasal endotracheal tube exchange have been used in patients with bleeding esophageal varices. Direct laryngoscopy and fiberoptic bronchoscopy are the most popular and reliable methods of tracheal intubation, but they rely on direct visualization, which was severely compromised in this case. Moreover, both techniques disrupt ventilation until a new endotracheal tube is placed properly. Although the combination of a fiberoptic bronchoscope and an endotracheal tube exchanger is a well established method of exchanging endotracheal tubes and allows continuous ventilation,<sup>1,2</sup> it is not ideal in this case, because it is difficult to introduce the fiberoptic bronchoscope into a trachea in the presence of blood.

We found four major advantages to using the newly designed endotracheal tube exchanger. First, it does not rely on direct visualization. Second, it minimizes the disruption of ventilation during the endotracheal tube exchange. Third, it is easier to perform than laryngoscopy and fiberoptic bronchoscopy. Last, and most important



## CORRESPONDENCE

is the security afforded by introducing the endotracheal tube exchanger through the original endotracheal tube to minimize the chances of losing control of the airway.

One disadvantage of this technique is, if a new endotracheal tube does not go into the trachea for any reason, the airway must be secured immediately by laryngoscopy, cricothyroidotomy, *et cetera*. Therefore, we suggest that only well trained anesthesiologists or intensivists familiar with and experienced in emergency airway management attempt to use this technique.

**Yoshinori Nakata, M.D.**  
Clinical Fellow  
Department of Emergency Medicine  
Yale New Haven Hospital  
20 York Street  
New Haven, Connecticut 06504

**Yoshinari Niimi, M.D., Ph.D.**  
Associate Professor  
Department of Anesthesiology  
Teikyo University School of Medicine  
Ichihara Hospital  
3426-3 Anesaki  
Ichihara, Chiba 299-01  
Japan

## References

1. Benumof JL: Additional safety measures when changing endotracheal tubes. *ANESTHESIOLOGY* 75:921-922, 1991
2. Wright TM, Vinayakom K: Endotracheal tube replacement in patients with cervical spine injury. *ANESTHESIOLOGY* 82:1307-1308, 1995

(Accepted for publication September 13, 1995.)

Anesthesiology  
83:1381, 1995  
© 1995 American Society of Anesthesiologists, Inc.  
Lippincott-Raven Publishers

## Spoons to Assist the Insertion of the Laryngeal Mask Airway

*To the Editor:*—The laryngeal mask airway (LMA) has significantly changed airway management in the practice of anesthesia. For most patients, the insertion of this airway is simple, straightforward, and uneventful. However, the recommended technique for insertion of the LMA involves at least partial insertion of fingers into the patients' mouth, which in a nonparalyzed patient, exposes the physician to the risk of being bitten. Also, the teeth can tear the protecting glove. Occasionally, the LMA is positioned in the nasopharynx without being immediately recognized.<sup>1</sup>

I have used a set of measuring spoons (fig. 1) to facilitate insertion of the LMA. After induction of anesthesia, a spoon of the appropriate size is inserted into the patient's mouth with the concave side facing the tongue. After insertion of the spoon, a well lubricated LMA of the appropriate size is inserted into the space between the spoon and the tongue. The concave surface of the spoon is used to shield the soft palate and deflect the tip of the LMA toward the larynx. Placement of the LMA can be achieved easily in patients with minimal mouth opening. In addition, the health hazards for the anesthesiologist associated with LMA placement are eliminated.

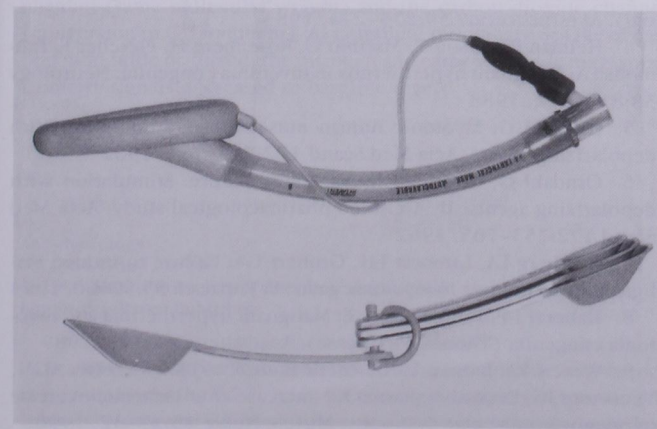
The plastic spoons are firm, and the edges are not sharp. I have found that the one-tablespoon size can be used in a normal-size adult male patient (LMA number 4), the half-tablespoon size can be used in a normal-size adult female patient (LMA number 3), the one-teaspoon size can be used in a normal-size child (LMA number 2), and the half-teaspoon size can be used in an infant (LMA number 1).

**Y. James Kao, Ph.D., M.D.**  
Department of Anesthesiology  
University of California, Irvine, Medical Center  
101 City Drive South  
Orange, California 92668

## Reference

1. Ball AJ: Laryngeal mask misplacement: A nonproblem. *Anesth Analg* 81:204, 1995

(Accepted for publication September 14, 1995.)



**Fig. 1.** The side-by-side placement of a number 4 laryngeal mask airway to the one-tablespoon measuring spoon. The other three measuring spoons discussed are attached to the same ring.