

## CASE REPORTS

Anesthesiology  
83:1355-1359, 1995  
© 1995 American Society of Anesthesiologists, Inc.  
Lippincott-Raven Publishers

## Paraplegia, Epidural Analgesia, and Thoracic Aneurysmectomy

Dermot R. Fitzgibbon, M.B., B.Ch., B.A.O., F.F.A.R.C.S.I.,\* Beth Glosten, M.D.,† Ian Wright, M.B., B.S., M.R.C.P., F.R.C.A.,†  
Raymond Tu, M.D.,‡ L. Brian Ready, M.D., F.R.C.P.C.§

PAIN after thoracotomy is one of the most intense clinical postoperative pain experiences known.<sup>1</sup> Thoracic epidural local anesthetics are administered with the aim of eliminating or reducing pain by creating a circumscribed band of dense analgesia in the dermatomal region of the thoracotomy incision.<sup>2</sup> Paraplegia is a rare complication of epidural anesthesia. Data relating to problems of paraplegia associated with epidural catheterization refer to lumbar, rather than thoracic, placement. A review of more than 750,000 epidural anesthetics estimated an incidence of 1:11,000 showing sustained neurologic deficits.<sup>3</sup> Kane's review<sup>4</sup> found three patients with permanent paralysis or paresis in a series of 50,000 epidural anesthetics. Of 32,718 cases, Dawkins<sup>5</sup> reported an incidence of transient neurologic lesions of 0.1% and permanent lesions of 0.02%.

We describe a case of delayed permanent paraplegia in a patient who underwent thoracic aneurysmectomy and received thoracic epidural local anesthetic postoperatively for pain control.

### Case Report

A 74-yr-old man developed severe chest pain radiating through to his back while playing golf. He had a 4-yr history of hypertension and, 7 months previously, had undergone a repair of an infrarenal abdominal aortic aneurysm without complications. Thoracic computerized tomography at the admitting hospital revealed a 5-cm aneurysm extending from approximately the 6th to the 10th thoracic

vertebral level. After treatment with meperidine and an infusion of nitroglycerin, his blood pressure was stabilized at 120 mmHg systolic down from 180 mmHg, and he was transferred to our institution. On admission, he was free of pain, had intact peripheral pulses with no murmurs or evidence of heart failure, and had no peripheral or carotid bruits. His blood pressure was controlled with infusions of sodium nitroprusside and esmolol, and, 3 days later, he was brought to the operating room for repair of his descending thoracic aortic aneurysm. The operation was uneventful. The patient was monitored using radial and femoral arterial catheters, pulmonary artery catheter, and transesophageal echocardiography. Mean arterial blood pressure and heart rate were controlled within 20% of baseline by adjusting depth of anesthesia and infusing nitroglycerin and esmolol as appropriate. After anticoagulation with 10,000U of heparin, partial left atriocaval bypass was established. Distal aortic pressure was maintained at 55–85 mmHg. The aorta was cross clamped between the 4th and 11th thoracic vertebral levels for a total of 31 min, and a #28 Dacron graft (Hemashield, Meadox Medical, Oakland, NJ) was inserted. It was noted that there were "minimal intercostals present in the area excised with approximately five very small branches overseen."

Postoperatively, the patient was transferred to the intensive care unit, his trachea was intubated, his lungs were ventilated, and he was hemodynamically stable. Four hours after the procedure, the trachea was extubated and the patient was noted to be moving all four extremities. Intravenous analgesia was provided with a morphine patient-controlled analgesia device. Because of problems with pain control, inability to cough, and oxygen saturation in the mid-80s in spite of supplemental oxygen, the Pain Service was consulted regarding the possible use of a thoracic epidural for postoperative analgesia. At the time of consultation (8 h after surgery), the patient was deemed neurologically intact and had normal coagulation (platelet count, prothrombin time, partial thromboplastin time, and thromboelastography values were within normal limits). The patient's systolic blood pressure varied from 100 to 110 mmHg with heart rates varying between 70 and 76 beats/min. The patient was awake, conversant, and consented to the procedure. Under sterile conditions, a paramedian approach at T<sub>6/7</sub> interspace with an #18-G Tuohy needle was chosen. Using loss of resistance to saline technique, the epidural space was identified at 5.5 cm and the catheter was placed 3 cm into the space. No paresthesiae were elicited during placement. With negative aspiration of blood and cerebrospinal fluid (CSF), a test dose of 3 ml of lidocaine 1% with epinephrine 1:200,000 was given. No alterations in heart rate or blood pressure were detected. Five minutes after injection of the test dose, there was no evidence of motor or sensory block. Fifteen minutes after the test dose, a further 5 ml lidocaine 1% with epinephrine 1:200,000 was injected. Over the next 15 min, the patient reported a diminution in pain. A sensory

\* Acting Assistant Professor, Department of Anesthesiology.

† Assistant Professor of Anesthesiology.

‡ Fellow, Department of Radiology.

§ Professor of Anesthesiology; Director of Acute Pain Services.

Received from the Departments of Anesthesiology and Radiology, University of Washington, Seattle, Washington. Submitted for publication March 24, 1995. Accepted for publication July 19, 1995.

Address reprint requests to Dr. Fitzgibbon: Department of Anesthesiology, Box 356540, University of Washington, 1959 NE Pacific Street, Seattle, Washington 98195.

Key words: Anesthesia: epidural. Aneurysm: thoracic. Paraplegia.



## CASE REPORTS

block to pinprick from T<sub>4</sub> to T<sub>11</sub> was demonstrated. Systolic blood pressure and heart rate remained unchanged. Forty minutes after injection of local anesthetic, the patient reported onset of bilateral lower extremity warmth and heaviness. On examination, the patient demonstrated profound bilateral motor paresis in the lower extremities, with an upper sensory level of anesthesia to pinprick to T<sub>5</sub> bilaterally. Blood pressure and heart rate were unchanged from pre-block values. We were concerned that the injection of lidocaine had been intrathecal and elected to observe the patient and to retest the catheter once the block had resolved. Ninety minutes after institution of the block, the patient became hemodynamically unstable on turning (systolic blood pressure 73 mmHg and heart rate 45 beats/min). Lower extremity paresis persisted with an unchanged upper sensory level at T<sub>5</sub> bilaterally. Because of concerns of an epidural hematoma or spinal cord ischemia, neurology and neurosurgical opinions were sought. Six hours after institution of the block, a thoracic magnetic resonance imaging (MRI) study was ordered. This study demonstrated normal thoracic cord and CSF signal characteristics on T-1 sequences. No definite explanation for persistent paresis was determined by this study, but direct cord trauma as a result of epidural placement could not be excluded. On T-2 sequences, the heterogenous signal within the CSF around the cord represents hemorrhage without evidence of cord compression (fig. 1). Location of the epidural catheter tip could not be determined because of movement artifact. Twenty-four hours after epidural placement and with the neurologic status unchanged, the MRI was repeated. This study clearly showed development of markedly abnormal high T-2 cord signal to the T<sub>10</sub> level at which normal low cord signal is maintained, and was most indicative of spinal cord ischemic change (fig. 2). There was no evidence of epidural hematoma nor direct cord trauma.

Five months after the procedure, there is no sensation below the T<sub>5</sub> dermatome level, and the patient has a neurogenic bowel and bladder and has no movement in the lower extremities.

### Discussion

The etiology of paraplegia in this case is spinal cord ischemia as demonstrated by MRI (fig. 2). The cause of ischemia is interruption of spinal cord blood flow. The relative contribution of the surgical and anesthetic techniques is unknown. Possible contributory factors are considered.

Ischemic damage to the spinal cord can occur after repair of a descending thoracic aneurysm.<sup>6</sup> The spinal cord is supplied by one anterior spinal artery and two posterior spinal arteries. The anterior spinal artery relies on reinforcement of its blood supply by six to eight medullary arteries, the most important and largest of which is the artery of Adamkiewicz. Multiple levels of the cord do not receive feeding medullary branches, thus leaving watershed areas that are particularly susceptible to ischemic injury. The tenuous collateral anastomosis of the anterior spinal artery in the mid-thoracic region places segments of the spinal cord in jeopardy during aortic occlusion or hypotension. Dam-

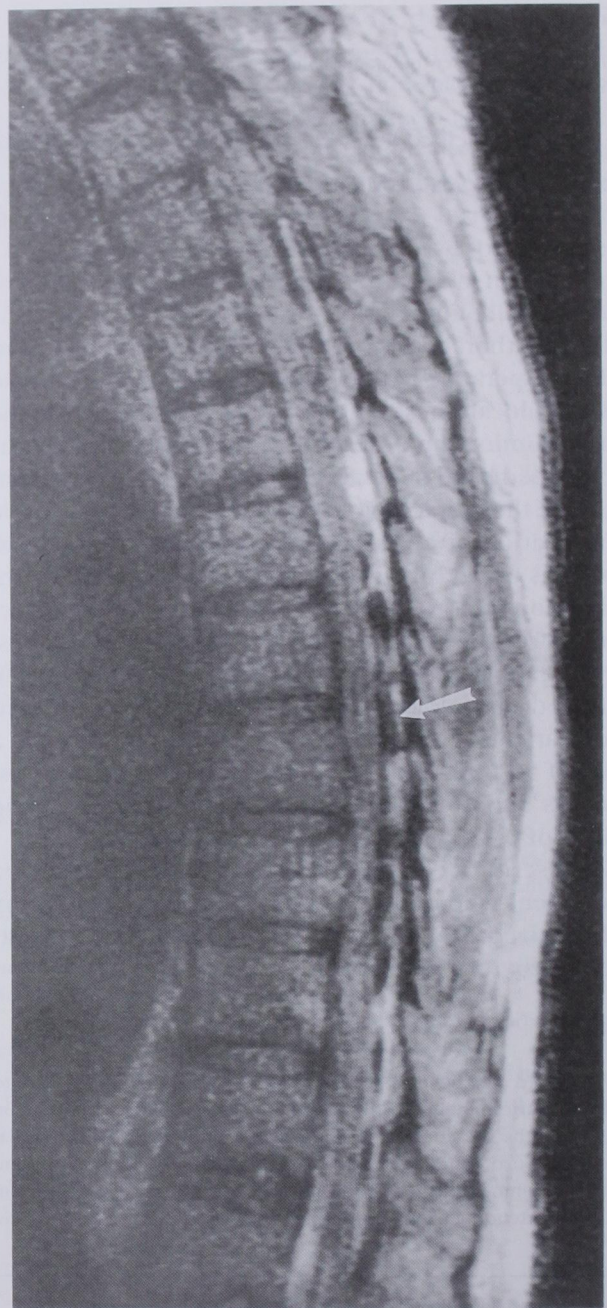


Fig. 1. On T-2 sequences, heterogenous signal within the CSF around the cord (arrow) represents hemorrhage.

age may result from either actual surgical dissection of the artery of Adamkiewicz (because the origin is unknown) or exclusion of the origin of the artery by cross clamps (usually applied between T<sub>5</sub> and L<sub>1</sub>). Cross clamping of the proximal descending aorta interrupts



## CASE REPORTS

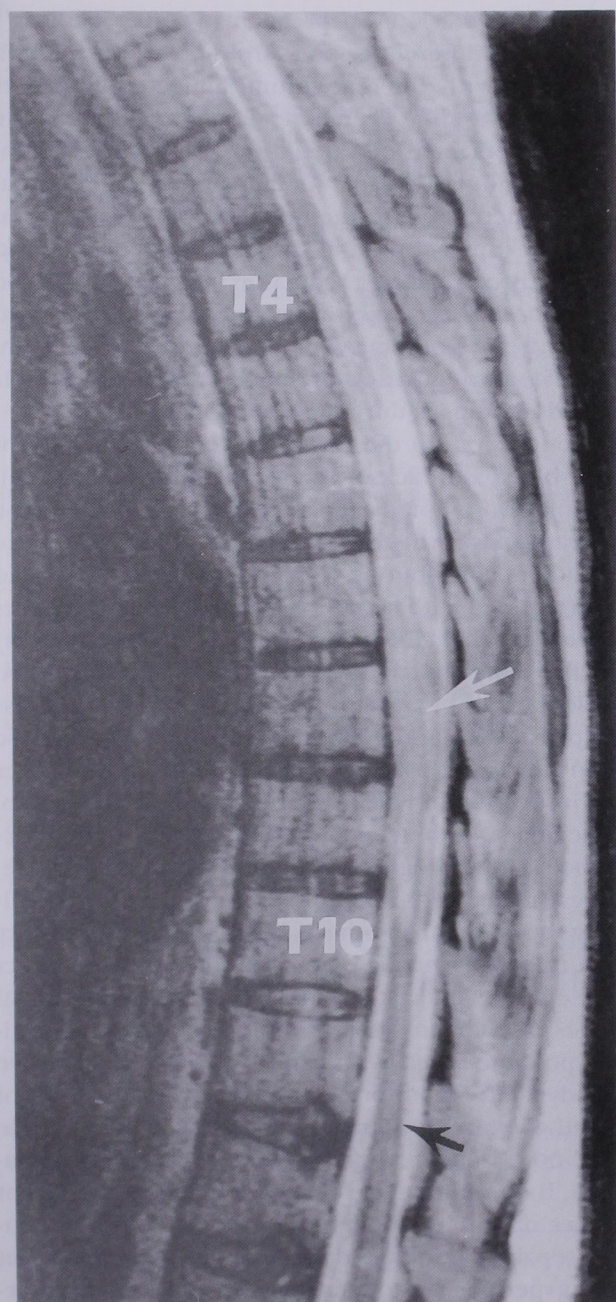


Fig. 2. Twenty-four hours later, repeat MRI clearly shows development of abnormally high T-2 cord signal (white arrow) to the tenth thoracic level at which normal low cord signal is maintained (black arrow). Vertebral levels are represented by T4 and T10. The MRI finding is most indicative of spinal cord ischemic change.

the blood supply to the area supplied by the aortic segment distal to the clamp. In dogs, clamping the thoracic aorta distal to the left subclavian artery produces a 94% decrease in spinal cord blood flow.<sup>7</sup> The like-

lihood of postoperative paraplegia rises significantly if the duration of cross clamping exceeds 30 min.<sup>8</sup>

The overall incidence of paraplegia after descending and thoracoabdominal aneurysmectomy varies between 5 and 21%,<sup>9,10</sup> with the highest incidence noted in patients with extensive thoracoabdominal disease.<sup>10</sup> Crawford *et al.*<sup>10</sup> reported neurologic deficits in a series of 198 patients undergoing descending thoracic or thoracoabdominal aneurysm repair. Postoperative deficits were defined as immediate if present at the time of recovery from anesthesia and delayed if they occurred subsequently. Fifteen patients (12 paraplegia and 3 paraparesis) had evidence of immediate deficits. Twenty patients (9 paraplegia and 11 paraparesis) had delayed deficits. These delayed deficits were first seen at times varying from 12 h to 21 days. In most cases, a precipitating cause was not identified, although some instances of delayed neurologic deficits were noted in association with complications that caused a reduction in blood flow. Delayed deficits were considered to be caused by factors that amplified subclinical ischemic states that had occurred intraoperatively (myocardial infarction or hypotension), as well as underlying atherosclerotic vascular disease. Delayed paraplegia occurring with postoperative hypotension may be seen in patients who have marginally adequate collateral circulation and who have had the artery of Adamkiewicz resected. Animal studies<sup>11</sup> implicate temporary cord ischemic times of 21 min as a significant contributor to delayed-onset paraplegia occurring between 14 and 48 h after occlusion. Our patient had several risk factors for spinal cord ischemia: extensive thoracoabdominal aneurysmal disease as evidenced by two aneurysmal repairs, and an ischemic cross-clamp time of significant duration (31 min).

Possible factors associated with epidural block that may contribute to a neurologic deficit include direct trauma (needle/catheter), infection, hematoma, neurotoxic reaction to injected agent, and ischemia (interruption of cord blood flow by hypotension, local anesthetic, epinephrine, spasm of spinal arteries, or a pressure effect from volume of epidural injectate). Although definite assessment of catheter tip placement could not be made because of movement artifact, direct cord trauma, abscess, and hematoma formation were excluded by MRI in this case.

Magnetic resonance imaging is the imaging modality of choice to demonstrate subtle intrinsic spinal cord abnormalities.<sup>12</sup> The typical MRI findings of spinal cord infarction should be assessed in the appropriate clinical



## CASE REPORTS

setting, *i.e.*, postthoracoabdominal aneurysm repair, because similar imaging findings may also be found with cord tumor and demyelinating disease. The evolution of hemorrhage and edema in an ischemic cord is responsible for the T-2 prolongation of signal. The markedly abnormal high T-2 cord signal, extending from the 4th to the 10th thoracic level at which normal low cord signal is maintained, is most indicative of cord ischemic changes (fig. 2). Although the MRI does not indicate a possible etiology for the observed ischemic changes, the large signal abnormality accounts more for a vascular abnormality than for focal (direct cord) trauma. The extensive area of cord infarcted implicates a widespread devascularization process. Some blood was observed within the subarachnoid space at 6 h (fig. 1), which persisted at 24 h, although epidural fluid collections or cord compression were not identified (figs. 1 and 2). The presence of subarachnoid blood may indicate an element of indirect trauma during catheter placement, although the frequency of this occurrence during thoracic epidural catheter placement is undefined. The possibility of blood in the subarachnoid space contributing to spinal artery spasm must be considered. Although data on the effects of blood in the thoracic subarachnoid space on spinal cord blood flow are lacking, there is ample evidence that the presence of subarachnoid blood in the basal cisterns is the cause of cerebral vasospasm after an intracranial subarachnoid hemorrhage, but only after several days have elapsed.<sup>13</sup>

A direct neurotoxic effect on the spinal cord from the lidocaine used appears unlikely. Although high concentrations of lidocaine have proved to be neurotoxic in rabbits, clinically relevant concentrations do not cause neurologic damage.<sup>14</sup> Local anesthetic agents and epinephrine may affect spinal cord blood flow. However, it is unknown whether local anesthetics or vasoconstrictors administered for epidural block directly or indirectly affect spinal cord blood flow in humans. Given the doses of lidocaine and epinephrine used in this case, and the conflicting reports in animal studies,<sup>15,16</sup> it is unlikely that these agents had a direct effect on spinal cord blood flow.

An epidural block may indirectly affect spinal cord blood flow as a result of changes in epidural pressure being transmitted across the dural membrane. A number of clinical reports<sup>17-19</sup> implicate alterations in CSF dynamics and blood flow after epidural injections. Shah<sup>17</sup> demonstrated that small fluid volumes injected into the lumbar epidural space produced a mean pressure in-

crease of 14 cm H<sub>2</sub>O in pregnant women. Thomas<sup>18</sup> has shown a differential pressure increase in the epidural space with different volumes injected. Pressures returned to baseline 3 min after a 2-ml injection, while pressures remained elevated after 3 min after a 6-ml injection. Similarly, Paul<sup>19</sup> demonstrated a differential pressure increase with the injection of 10 and 15 ml within the lumbar epidural space. Clinical data is lacking directly correlating a reduction in spinal cord blood flow with increases in epidural pressure secondary to an increase in epidural volume. In addition, it is unknown if autoregulation of spinal cord blood flow is affected in humans during epidural anesthesia.

In conclusion, in the case reported here, persistent motor block and lack of recovery from spinal or epidural block prompted aggressive evaluation. The cause of paraplegia in this case was spinal cord infarction. The factors contributing to paraplegia are unlikely to be determined with certainty. The surgical procedures (descending thoracic and abdominal aneurysm repairs) probably contributed by mechanisms of spinal cord devascularization and application of a thoracic cross-clamp. The role of the epidural anesthesia in this case in contributing to paraplegia is unknown. Forty minutes after institution of what initially appeared to be a typical segmental thoracic epidural block, the patient developed a neurologic deficit that essentially has remained unchanged. Scientific evidence directly implicating the epidural anesthesia is lacking. A contributory effect to cord ischemia by the volume/pressure effect of the epidural injectate or spasm of the radicular spinal arteries by thoracic subarachnoid blood are theoretically possible. Even with careful technique, invasive hemodynamic monitoring, and early evaluation of neurologic status, our patient experienced irreversible spinal cord ischemia that resulted in permanent paraplegia. It is important to remember that, in a significant number of patients undergoing thoracic aortic aneurysm repair, paraplegia develops that may present at varying periods postoperatively. A high-risk subcategory may be identified (extensive thoracoabdominal disease or prolonged cross-clamp time) and, in such patients, the possibility of variable, unexpected onset of paraplegia should be considered when selecting a method for postoperative pain relief.

## References

1. Loan WB, Morrison JD: The incidence and severity of postoperative pain. *Br J Anaesth* 39:695-698, 1967



## CASE REPORTS

2. Kavanagh BP, Katz J, Sandler AN: Pain control after thoracic surgery: A review of current techniques. *ANESTHESIOLOGY* 81:737-759, 1994
3. Usubiaga JE: Neurological complications following epidural anesthesia. *Int Anesthesiol Clin* 13:1-153, 1975
4. Kane RE: Neurologic deficits following epidural or spinal anesthesia. *Anesth Analg* 60:150-161, 1981
5. Dawkins CJ: An analysis of the complications of extradural and caudal block. *Anaesthesia* 24:554-563, 1969
6. Shenaq SA, Svensson LG: Paraplegia following aortic surgery. *J Cardiothorac Vasc Anesth* 7:81-94, 1993
7. Gelman S, Reves JG, Fowler K, Samuelson PN, Lell WA, Smith LR: Regional blood flow during cross-clamping of the thoracic aorta and infusion of sodium nitroprusside. *J Thorac Cardiovasc Surg* 85:287-291, 1983
8. Crawford ES, Crawford JL, Safi HJ, Coselli JS, Hess KR, Brooks B, Norton HJ, Glaeser DH: Thoracoabdominal aortic aneurysms: Preoperative and intraoperative factors determining immediate and long-term results of operations in 605 patients. *J Vasc Surg* 3:389-404, 1986
9. Hollier LH, Symmonds JB, Pairolero PC, Cherry KJ, Hallett JW, Gloviczki P: Thoracoabdominal aortic aneurysm repair: Analysis of postoperative morbidity. *Arch Surg* 123:871-875, 1988
10. Crawford ES, Mizrahi EM, Hess KR, Coselli JS, Safi HJ, Patel VM: The impact of distal aortic perfusion and somatosensory evoked

potential monitoring on prevention of paraplegia after aortic aneurysm operation. *J Thorac Cardiovasc Surg* 95:357-367, 1988

11. Moore WMJ, Hollier LH: The influence of severity of spinal cord ischemia in the etiology of delayed-onset paraplegia. *Ann Surg* 213:427-431, 1991
12. Yuh WT, Marsh EE, Wang AK, Russell JW, Chiang F, Koci TM, Ryals TJ: MR imaging of spinal cord and vertebral body infarction. *Am J Neuroradiol* 13:145-154, 1992
13. Mizukami M, Kawase T, Usami T, Tazawa T: Prevention of vasospasm by early operation with removal of subarachnoid blood. *Neurosurgery* 10:301-307, 1982
14. Ready LB, Plumer MH, Haschke RH, Austin E, Sumi SM: Neurotoxicity of intrathecal local anesthetics in rabbits. *ANESTHESIOLOGY* 63:364-370, 1985
15. Kozody R, Swartz J, Palahniuk RJ, Biehl DR, Wade JG: Spinal cord blood flow following sub-arachnoid lidocaine. *Can Anaesth Soc J* 32:472-478, 1985
16. Dohi S, Matsumiya N, Takeshima R, Naito H: The effects of subarachnoid lidocaine and phenylephrine on spinal cord and cerebral blood flow in dogs. *ANESTHESIOLOGY* 61:238-244, 1984
17. Shah JL: Influence of cerebrospinal fluid on epidural pressure. *Anaesthesia* 36:627-631, 1981
18. Thomas PS, Gerson JI, Strong G: Analysis of human epidural pressures. *Reg Anesth* 17:212-215, 1992
19. Paul DL, Wildsmith JA: Extradural pressure following the injection of two volumes of bupivacaine. *Br J Anaesth* 62:368-372, 1989

*Anesthesiology*  
83:1359-1361, 1995  
© 1995 American Society of Anesthesiologists, Inc.  
Lippincott-Raven Publishers

## Placement of a Right Atrial Air Aspiration Catheter Guided by Transesophageal Echocardiography

Steven Roth, M.D.,\* Solomon Aronson, M.D.†

ONE of the principal risks of the sitting position for neurosurgical patients is the possibility of life-threat-

ening air embolism. Use of a multiorificed central venous catheter is highly recommended as a means for aspirating air from the circulation should embolism occur.<sup>1</sup> The junction of the superior vena cava (SVC) and right atrium (RA) is the optimal position for maximal efficacy in aspirating air.<sup>2</sup> Conventional methods for placement of the catheter include the use of x-ray, fluoroscopy, or pressure waveform monitoring. These methods are time consuming, require additional personnel, and may not precisely localize the catheter at the RA-SVC junction. In addition, chest x-ray and fluoroscopy may expose personnel to radiation. Accordingly, the catheter is typically placed by interposing a stopcock with a metal connector into the fluid path of the catheter and connecting the stopcock to an ECG machine. The P wave is transduced as the catheter is

\* Associate Professor of Anesthesia and Critical Care; Chief, Neuroanesthesia.

† Associate Professor of Anesthesia and Critical Care; Chief, Cardiovascular and Thoracic Anesthesia.

Received from the Department of Anesthesia and Critical Care, University of Chicago, Chicago, Illinois. Submitted for publication April 13, 1995. Accepted for publication July 24, 1995.

Address reprint requests to Dr. Roth: Department of Anesthesia and Critical Care, University of Chicago, 5841 South Maryland, Box MC-4028, Chicago, Illinois 60637.

Key words: Embolism, air; right atrial catheter. Measurement technique: transesophageal echocardiography. Monitoring: central venous pressure.